

(Refer to page 206)

Answer: Right cervical rib compressing the subclavian vessels.

A cervical rib is an accessory rib arising from the C7 vertebral body (Figure 1_a), which is often an incidental finding on chest x-ray. It is a rare condition, occurring in less than 1% of the population but can vary from 0.58% in a Malaysian population to as 6.2% in Turkish population.¹ It can however, be highly significant clinically, with patients presenting with symptoms of neurovascular compromised due to compression on the neurovascular bundle. Cervical rib is one cause of 'thoracic outlet syndrome' is a result of direct impingement on the subclavian vessels and or brachial plexus.

Compression on the brachial plexus causing neurological symptoms, such as paraesthesia is more common than ischaemia due to vascular involvement.² Neurogenic

due to vascular involvement. Neurogenic symptoms usually arise following neck trauma in 80% of patients with cervical ribs, either following work-related injuries or repetitive stress or road traffic accidents.³ In 20% of patients with cervical ribs, symptoms appeared spontaneously.

Indications for surgical resection of the accessory rib are disabling pain, paraesthesia and failure of conservative treatment. Surgery involves resection of the accessory rib with or without excising the first rib. Failure rate of surgical treatment is high in those with work-related injuries (42%) compared with those arising following RTA (26%) or spontaneously (18%).³ Surgical success rate is also higher if both cervical and first ribs are resected together.

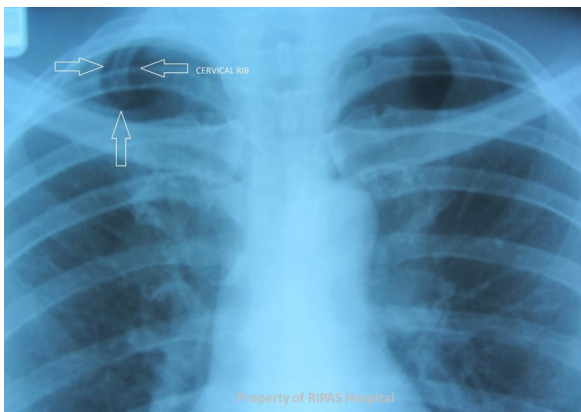


Figure 1_a: Annotated Chest X-ray (Figure 1, page 206) pointing at the cervical rib.

REFERENCES

- 1: Lukasz Spadinski, Tomasz Cecot, Agata Majos, Ludomir Stefanczyk, Wioletta Pietruszewska, Grzegorz Wysocki, Mirosław Topol, Michał Polgój. The epidemiological, morphological and clinical aspects of the cervical ribs in Humans. *Biomed Res Int.* 2016;2016:8034613. Published online 2016 Nov 15. doi: 10.1155/2016/8034613.
- 2: Dashti G, Ghasemi N. Evaluation of neurovascular complication of cervical ribs. *Anatomical Sciences.* 2015;12(3):111-114.
- 3: Sanders RJ, Hammond SL. Management of cervical ribs and anomalous first ribs causing neurogenic thoracic outlet syndrome. *J Vasc Surg.* 2002;36(1):51-6.