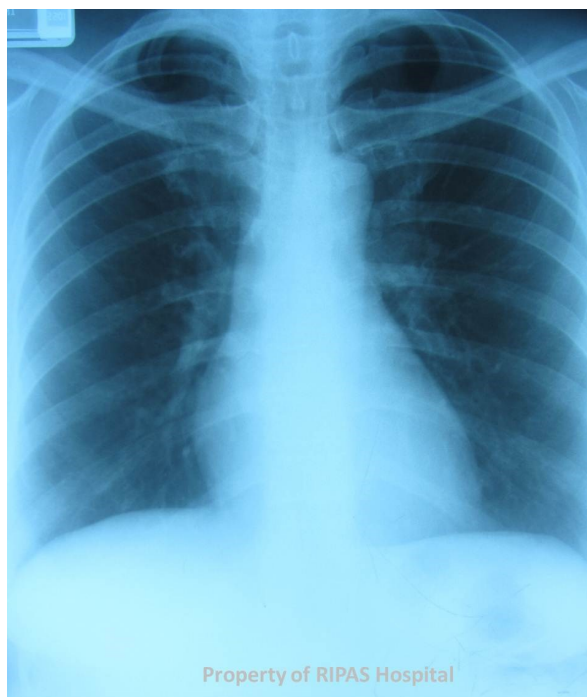


**Ian BICKLE and Chee Fui CHONG****Figure 1**

A 35 years old woman was referred to a vascular clinic with recurrent intermittent painful bluish discolouration of her right finger tips which comes about whenever she played tennis vigorously. These usually resolved after resting but lately it seems to last longer and more painful. She decided to visit her GP where she further admitted that she has been getting cramps in her right hand and fingers. The GP decided to take a chest radiograph as shown in Figure 1 and subsequently referred to the Vascular Clinic at the main Tertiary referral centre.

**What is the diagnosis?****Answer:** refer to page 220

**Correspondence author:** Mr Chee Fui CHONG,  
Department of Radiology, RIPAS Hospital, Bandar Seri  
Begawan BA1710, Brunei Darussalam.  
Email: [william.chong@moh.gov.bn](mailto:william.chong@moh.gov.bn)