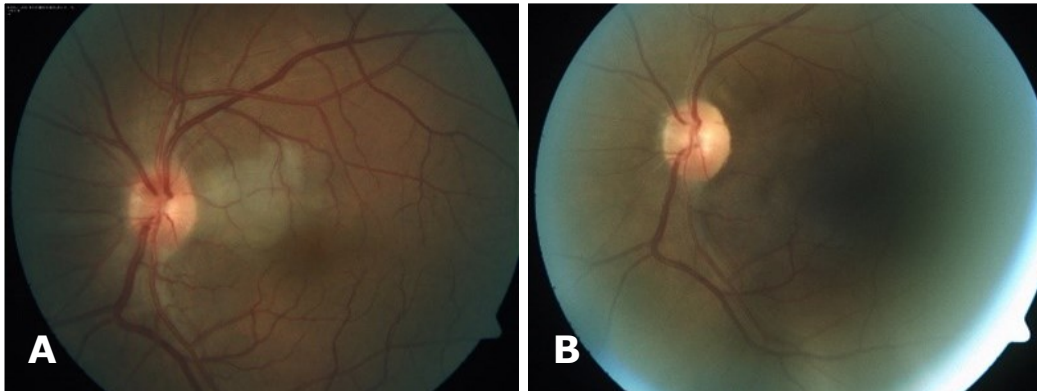


**Chow Chin LOH, Hanizasurana HASHIM, Nor Fariza NGAH**



A 46-year-old gentleman with no previous medical comorbid presented with acute, painless visual reduction in the left eye for 12 hours duration. He was a chronic smoker of 30 cigarettes per day for the past 20 years. He denied associated headache, jaw claudication, nor other connective tissue disease symptoms. On clinical examination, his visual acuity was counting finger at a distance of one foot on his left eye and 6/9 on his right. Findings of anterior segment examinations of both eyes were unremarkable. Fundus examinations are as image shown (**Panel A**). Immediate ocular massage using Goldman 3 mirror, applying self-rebreathing bag and anterior chamber paracentesis were performed. Fundus examinations one month later as shown in (**Panel B**). What is the diagnosis?

**What is diagnosis?**

**Answer:** refer to page 182

**Correspondence author:** Chow Chin LOH  
Blok A-703, Kuaters Hospital Selayang,  
Hospital Selayang, Lebuhraya Selayang-Kepong,  
68100, Batu Caves, Selangor, Malaysia.  
Tel: +6016-4382338  
E mail: flcc10@yahoo.com