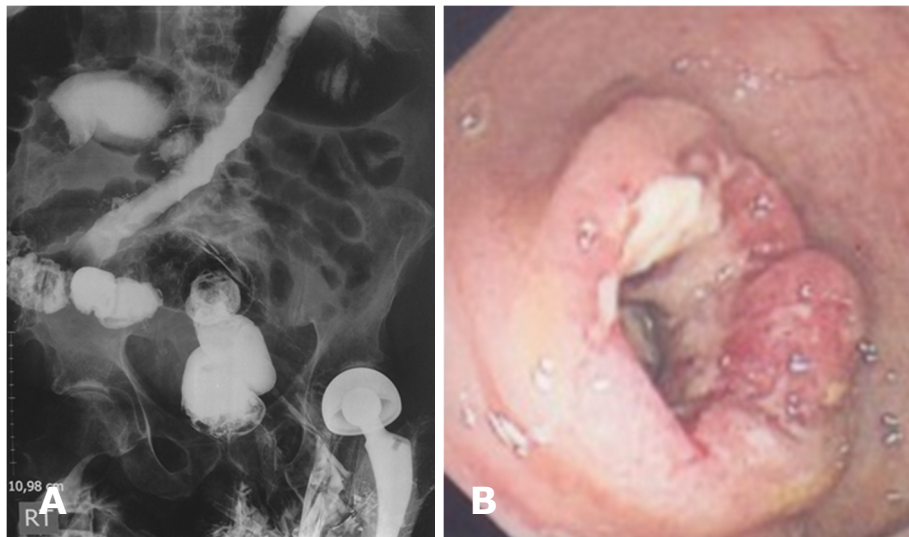


Shazana NOR, Kai Shing KOH, Sambandamurthy SHANKARAKUMAR, Kim Khee TAN, Pemasari Upali TELISINGHLE, Vui Heng CHONG



An elderly Caucasian man presented with a week history of increasing lower abdominal discomfort and anorexia. This was associated with altered bowel habits for the previous two months. His background history was significant for a recent diagnosis of metastatic left parotid cancer, previous left hip replacement, hypertension, hyperlipidaemia and asthma. His presenting abdominal radiograph showed dilated transverse colon with a cut-off at the splenic flexure and dilated loops of small bowel. A barium enema was done (**Panel A**) followed by a colonoscopy which showed abnormality in the sigmoid colon (**Panel B**).

What is the diagnosis?

Answer: refer to page 49

Correspondence author: Vui Heng CHONG
Department of Medicine, RIPAS Hospital
Brunei Darussalam
Tel: 2242424 Ext 5233
E mail: chongvuih@yahoo.co.uk