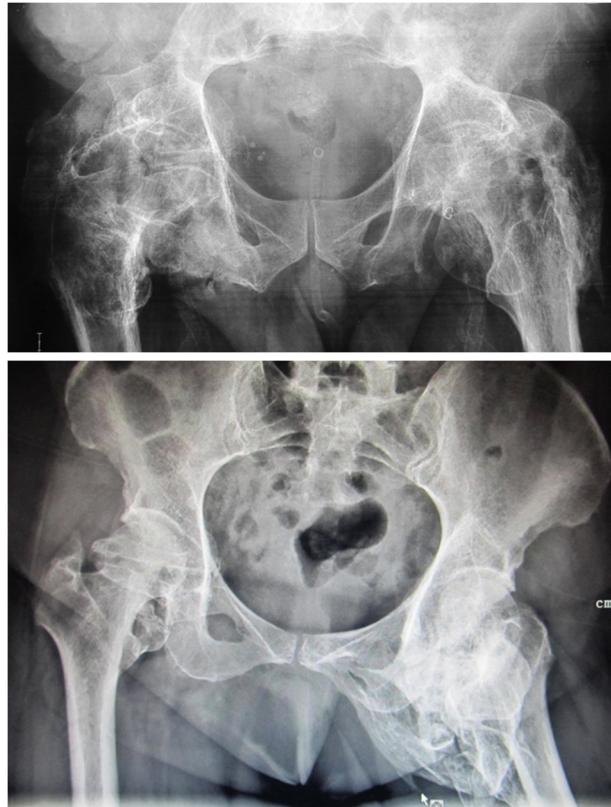


**Ian STEWART, Sonali PANDE, Ketan PANDE**



A 52 year-old-men was involved in a road traffic accident resulting in thoracic spinal cord injury and paraplegia. After surgery and rehabilitation, he complained of progressive restriction of movements of the lower limbs during follow up. On examination there was complete loss of movements at the hip joints with the right hip fixed in adduction and left hip in abduction. Plain radiograph of the pelvis was requested (**Panel A**). A 50-year-old lady sustained head injury in a road traffic accident. She was comatosed for more than two months. During follow up she was noted to have developed restriction of movements of the left hip. She is now able to walk but her left hip is fixed in abduction. Recent pelvis radiograph (**Panel B**) confirmed the cause of her symptoms.

### **What is the diagnosis?**

**Answer:** refer to page 47

**Correspondence author:** Ketan C Pande  
Department of Orthopaedics, RIPAS Hospital  
Brunei Darussalam  
Tel: 2242424 Ext 5614  
E mail: ketanpande@yahoo.com