

# A rare case of a peritoneal liposarcoma arising from the parietal peritoneum

Pei Pei ONN <sup>1</sup>, Kai Shing KOH <sup>1</sup>, Chean Leung CHONG, Edwin LIM <sup>2</sup>, Vui Heng CHONG <sup>3</sup>  
<sup>1</sup> Department of Surgery, <sup>2</sup> Department of Pathology and <sup>3</sup> Department of Medicine,  
RIPAS Hospital, Brunei Darussalam

## ABSTRACT

Liposarcoma is a mesenchymal tumour that arises from the adipose tissue, and is most commonly found in the extremities and retroperitoneum. Its incidence peaks in the fourth to sixth decades of life. We report a rare case of a pelvic peritoneal liposarcoma that was detected incidentally by imaging in a 71-year-old man who was evaluated for lower gastrointestinal bleeding. The tumour arose from the parietal peritoneum which has not been previously reported.

**Keywords:** Lipoblast, neoplasm, peritoneal, liposarcoma, parietal peritoneum

## INTRODUCTION

Liposarcoma is a mesenchymal malignant tumour that arises from the adipose tissue and commonly occurs in the extremities and retroperitoneum. <sup>1,2</sup> Peritoneal liposarcoma is less common and are usually found in the small bowel mesentery. <sup>1-3</sup> Primary intraperitoneal liposarcoma is extremely rare. We report a rare case of a pelvic peritoneal liposarcoma that arose from the parietal peritoneum which has not been previously reported.

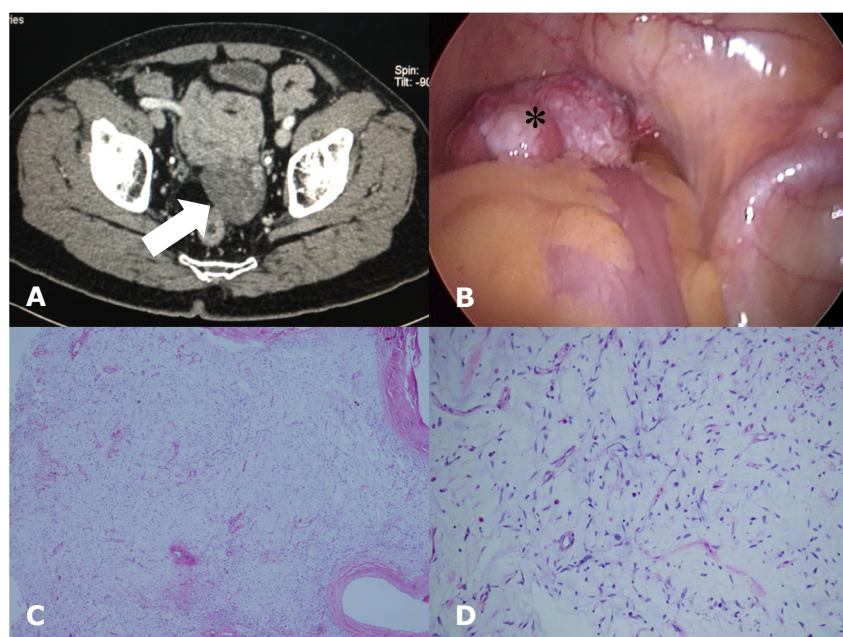
## CASE REPORT

A 71-year-old man was admitted with rectal bleeding. His past medical history included hypercholesterolemia, previous right inguinal

hernia repair and transurethral resection of the prostate for benign prostate hypertrophy. On examination he was diaphoretic, tachycardic with postural hypotension. Abdominal examination revealed no tenderness or any palpable mass.

Blood investigations (complete blood count, renal, liver and clotting profiles) were all normal. However the haemoglobin dropped from 12.3 g/dL (normal 13.5 to 17) on admission to 9.3 g/dL the following day. Colonoscopy to ileum revealed a flat polyp (12mm) in the sigmoid and several small diverticuli in the ascending colon. A computed-tomography scan showed a mass (5.0 x 5.1cm) with focal patchy areas of enhancement that seem to be attached to the ileal loop slightly to the left of midline (Figure 1a).

**Correspondence author:** Vui Heng CHONG  
Department of Medicine, RIPAS Hospital,  
Bandar Seri Begawan BA 1710  
Brunei Darussalam  
Tel: +6732242424 Ext 5233  
E mail: chongvuih@yahoo.co.uk



**Figure 1: A) Axial CT imaging showing the tumour (Arrow) in the distal ileum, B) laparoscopic image of the liposarcoma (\*), C) low power microscopy showing a myxoid lesion with prominent vasculature (H&E, x4), and D) high power microscopy showing spindle cells in a myxoid stroma with chicken-wire vasculature (H&E, x40).**

The patient was referred to the surgical services and proceeded to laparoscopic resection. The operative findings revealed a fatty lobulated mass (5 x 7cm) in the pelvis arising from the anterior aspect of the apex of the rectovesical pouch (Figure 1b). The large and small bowels were assessed and no Meckel's diverticulum or any other lesions was found. The tumour was resected without any complication. The histopathology reported as follow: "a tumour comprising of spindle cells was noted in a richly vascularised myxoid stroma (Figures 1c and d). The spindle cells have hyperchromatic elongated, stellate to plump nuclei with scattered multinucleated giant cells. Lipoblasts are seen. A few perivascular foci showing increased cellularity are present but mitotic activity is only rare (<1 per HPF). Proliferative index with ki67 is low (1-2%). There is prominent delicate branching "chicken-wire" capillary network in the myxoid stroma. Occasional haemorrhagic foci

are seen. Several ectatic blood vessels with hyalinised wall and thrombus formation are also present. Round cells and dedifferentiated high grade components are absent. Necrosis is also not seen. The lesion is 0.6cm away from the nearest resection margin. The findings were that of a myxoid liposarcoma – Grade 2 French Federation of Cancer Centres System of Grading (FNCLCC)."

Post-operatively, the patient made an uneventful recovery and was discharged several days later. He remained well without any problem or recurrence of bleeding two years after resection.

## DISCUSSION

Liposarcoma accounts for between 10% and 12% of all soft tissue sarcomas.<sup>1</sup> It is primarily a tumour of adults with a peak incidence between the fourth and sixth decade of life. It has preponderance for the lower ex-

limbs and the retroperitoneum, while occurrence in other locations such as the upper extremities and the head and neck regions have also been reported.<sup>2</sup> Other sites such as our case where the tumour arose from the pelvic parietal peritoneum are uncommon or extremely rare. To date, there have only been seven cases of primary peritoneal liposarcoma reported in the literature.

Histologically, liposarcoma can be subdivided into five categories: well-differentiated, round-cell, myxoid, pleomorphic, and mixed; with the most common subtypes being well-differentiated and myxoid.<sup>4</sup>

In most cases, the diagnoses are late due to late presentations. The tumour tends to grow to a large size before presentations. Most patients present with nonspecific symptoms of mass effects; increasing abdominal girth to compression on adjacent organs or structures.<sup>3, 5, 6</sup> The prognosis depends on the size, location and the histologic pattern of the tumour, with positive surgical margins being key predictors for local recurrence.<sup>1</sup> The 5-year survival rate for myxoid liposarcoma is over 75%. Myxoid liposarcoma also has an unusual propensity for distant metastasis compared to the other types of liposarcoma.<sup>7</sup>

In conclusion, we report a rare case of peritoneal liposarcoma in a patient that was detected incidentally while investigation for gastrointestinal bleeding. The lesion was smaller than those reported in the literature. The patient remained well without evidence of recurrence two years after resection.

#### REFERENCES

- 1: Niromanesh S, Mirzaie F, Bateni A. Primary peritoneal liposarcoma in a middle age woman. *Acta Med Iran.* 2009; 47:431-3.
- 2: Munk PL, Lee MJ, Janzen DL, et al. Lipoma and liposarcoma: Evaluation using CT and MR imaging. *AJR Am J Roentgenol.* 1997; 169:589-94.
- 3: Jukic Z, Brcic I, Zovak M, et al. Giant mixed-type liposarcoma of the mesentery: case report. *Acta Clin Croat.* 2012; 51:97-101.
- 4: Hashimoto H, Enjoji M. Liposarcoma. A clinicopathologic subtyping of 52 cases. *Acta Pathol Jpn.* 1982; 32:933-48.
- 5: Khan MI, Zafar A, Younas M, et al. Huge mesenteric liposarcoma. *J Pak Med Assoc.* 2013; 63:775-7.
- 6: Sato H, Minei S, Sugimoto S, et al. Multicentric liposarcoma. *Int J Urol.* 2004; 11:1133-5.
- 7: Tomita H, Yamaguchi K, Matsuo M, et al. Metastatic myxoid liposarcoma in the mesentery: what is debated? Case report and a review of the literature. *Am Surg.* 2006; 72:68-70.
- 8: Cerullo G, Marrelli D, Rampone B, et al. Giant liposarcoma of the mesentery. Report of a case. *Ann Ital Chir.* 2007; 78:443-5.
- 9: Das G, Das BK. Giant lesser sac liposarcoma mimicking infected pancreatic pseudocyst. *Indian J Gastroenterol.* 2006; 25:157-8.