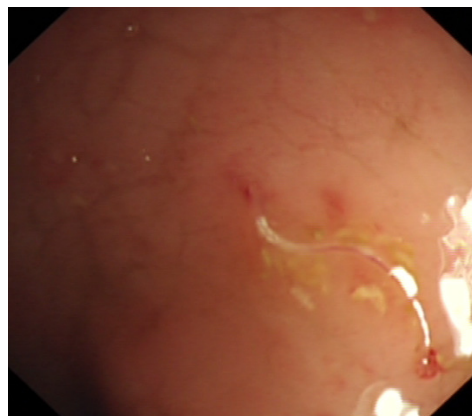


Babu Ivan MANI and Vui Heng CHONG

A 33-year-old man presented to district hospital with complaints of watery stool of one week duration. This was associated with colicky abdominal pain. He continued to have watery diarrhoea, six to seven times a day that persisted for more than 11 days despite receiving a course of antibiotic (Ciprofloxacin). Stool microscopic examination was negative for amoeba, ova, or cyst and stool culture was negative. There was progressive rise in the total white cell count WBC (27 to 36×10^9 ; Eosinophil counts 60% from 17%). A colonoscopy was done (**Panel:** *click on image to watch video*).

What is the diagnosis?

Answer: refer to page 265

Correspondence author: Babu Ivan MANI
Department of Medicine,
PMMPMHAMB Hospital, Tutong, TA 1141
Brunei Darussalam
Tel: +673 4260722 Ext 506/237, HP +673 8806532
E mail: babuivan@gmail.com