

Through and through carotid artery injury from a fish bone

Bathma Dhevi SUSIBALAN ^{1,2}, Zulkifli YUSOF ¹, Masaany MANSOR ¹,
Mohd Ayzam AHMAD ¹, Irfan MOHAMAD ²

¹ Department of Otorhinolaryngology, Hospital Sultanah Bahiyah, Alor Setar, Kedah,
and ² Department of Otorhinolaryngology-Head & Neck Surgery, School of Medical
Sciences, Universiti Sains Malaysia Health Campus, Kota Bharu, Kelantan, Malaysia

ABSTRACT

Ingested foreign bodies are one of the most commonly seen otorhinolaryngology emergencies. A uncommon complication is the migration from the oro-digestive tract. Presentation varies and depends on the types of foreign body and routes of migration. Reported presentations include thyroid lumps or abscess, unassuming skin granulations, and a discharging sinus. A high index of suspicion is required to diagnose this condition early. An initial positive neck radiograph for foreign body followed by negative oesophagoscopy is highly suggestive of migrations. We report the case of a migrated fish bone confirmed on radiological imaging and was found on surgical exploration to have pierced the common carotid artery through and through. This was successfully removed without any further complications.

Keywords: Common carotid artery, foreign body, migration, complications

INTRODUCTION

Foreign body (FB) migrating into the neck is a rare consequence of its ingestion. It is even rare to find a fish bone piercing the walls of the common carotid artery. Exploring such FB is rather a therapeutic challenge in view of its potential catastrophic complications.

The sharper the foreign body is, the higher the risk of perforation and thus facilitating migration going outside alimentary tract. ¹ When perforation occurs, it is facilitated by the strong contraction of the hypopharyngeal and crico-oesophageal muscle as they propel the food bolus into the oesophagus. This explains the higher risk of penetration and migration at levels of hypopharynx and cervical oesophagus. ¹

We report an interesting case of a migrated fish bone with a through and through perforation of the common carotid artery. Confirmation was made by radiological imaging. The patient was successfully treated with surgery without any complication.

CASE REPORT

A 21-year-old man presented with complaint of a fish bone stuck in his throat of one day duration. He could feel the FB located to the

Correspondence author: Irfan MOHAMAD,
Department of Otorhinolaryngology-Head & Neck
Surgery, School of Medical Sciences, Universiti
Sains Malaysia Health Campus, 16150 Kota Bharu,
Kelantan, Malaysia.
Tel: 609-7676420
E mail: irfankb@usm.my

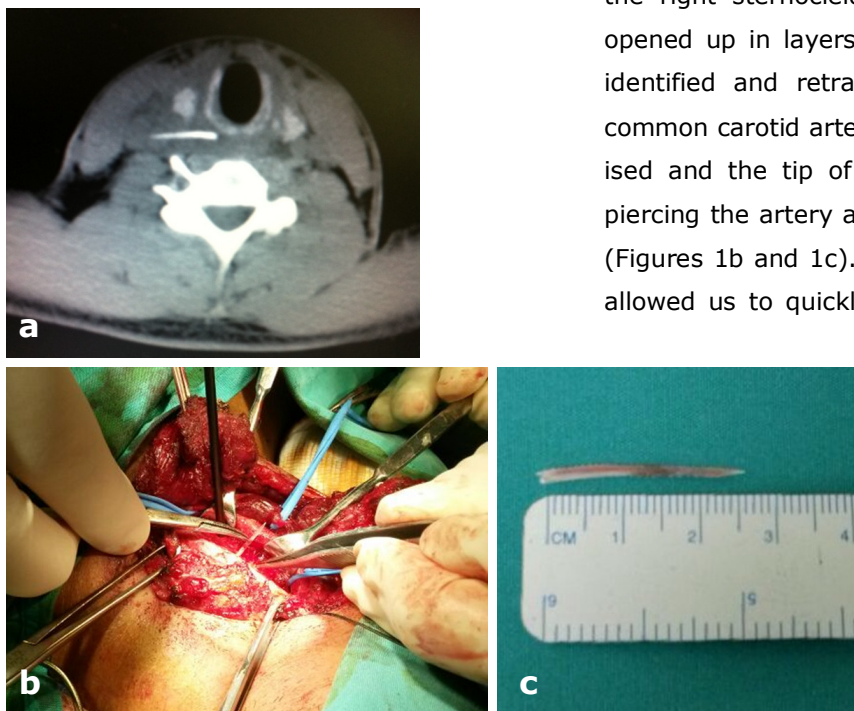
right side of his neck, corresponding to the level of the hyoid bone. He also complained of odynophagia but was still able to take fluid. There was no fever or drooling of saliva. He has no other significant medical or surgical history.

On review he was comfortable and was able to localise the site of pain on swallowing. Examination of the oral cavity was unremarkable. Even with the use of a rigid 70 degree scope, we were still unable to visualise the FB. A plain radiograph of the neck showed a vague opacity, suggestive of a fish bone at the C5 vertebra level. No FB was noted in the larynx or in the visualised trachea. As his symptoms persisted along with poor oral intake secondary to the odynophagia, we proceeded with a direct laryngoscopy and oesophagoscopy under general anaesthesia. Intra-operatively there was no FB seen at the oropharynx or the supraglottic region. Both the hypopharynx were clear. Oesophagoscopy

also negative. There was no region of localised pus, slough or foul smelling collection.

Post operatively, his symptoms did not improve and the pain persisted. It became more prominent over the right lateral surface of the neck. There was no sign or symptoms of mediastinitis. He was still unable to tolerate oral intake. We proceeded with an ultrasound scan of the neck. This showed a possible a FB near the right common carotid artery. The FB appeared to have pierced through the artery. An urgent computed tomography (CT) scan of the neck showed the fish bone in close proximity to the right common carotid artery and appeared to have pierced the carotid artery (Figure 1a). However no fluid collection or haematoma was noted at the site.

An emergency neck exploration was carried out under general anaesthesia. A skin incision was made 2-finger breadths below the right angle of mandible extending from the level of hyoid bone to the anterior border of the right sternocleidomastoid. The skin was opened up in layers, the sternocleidomastoid identified and retracted upwards. The right common carotid artery was carefully skeletonised and the tip of the fish bone was seen piercing the artery at the mid 3rd of its length (Figures 1b and 1c). Using finger palpation, it allowed us to quickly zoom into the involved



Figs. 1: a) An unenhanced axial computed tomography image showing a fish bone piercing through the right common carotid artery, b) intra-operatively, the fish bone is seen piercing through the right common carotid artery, and c) removed fish bone measured 2.5

region, identify and remove the FB with minimal tissue destruction. The fish bone was removed without any complications. The pierced site sealed itself and there was no tear or laceration seen at the artery wall. No repair of the artery was required. A surgical drainage tube was inserted and skin was closed. A Ryle's tube was inserted for commencement of feeding.

The patient did well post operatively and feeding was commenced via Ryle's tube. The drain was removed two days after operation and he started on oral feeding on the following day. There was no complication and he was discharged well on fourth day after the operation. He completed a five-day course of intravenous antibiotics, amoxycillin-clavulanic acid and metronidazole which was started even before the operation. A review after two weeks as outpatient also showed no complication.

DISCUSSION

Immediate localisation and removal of all FBs in the upper aerodigestive tract is imperative, particularly in cases of sharp objects. The likelihood of migration is higher with sharp objects. The FBs can migrate into the soft tissue of the neck, mediastinum, visceral structures such as the thyroid gland, and even major blood vessels. Complications of migrations that affect major vessels can lead to serious complications such as aorto-oesophageal fistula or worse carotid rupture.² Fortunately, there was no complications of vessel injury in our case.

The first investigation for patient with suspected oropharyngeal or oesophageal FB is a lateral neck radiograph. However not all

FBs will be seen in plain radiographs. However it has poor sensitivity (25%) but a reasonable specificity (86.3%) for detecting fish bones.¹ Furthermore, it cannot determine whether the FB migration has occurred. Calcified thyroid and cricoid cartilages can also masquerade as FBs. Therefore in cases where there is a positive finding on lateral neck radiograph but negative rigid oesophagoscopy, CT imaging is warranted. It provides spatial image of the migrated ingested FB, preoperative radiographic findings, which definitely helps in retrieval of the migrated FB.³

Interestingly, the duration of ingestion is not an indicator of migration. In one study of patient with migrated FBs, 75% presented within 24 hours of FB ingestion.⁴ However one study has also been reported that time interval between ingestion and visit to emergency department were risk factors for complications.⁵ If the interval is more than 48-hour with positive radiographic changes, the chances of complications are higher.⁵ The types of fish bone that usually migration is the sharp, linear fish bones rather than T-shaped ones.⁴ Horizontally-placed fish bones are also at higher chance of migration. The manner and forcefulness of swallowing and the shape of the FB may be the primary cause of migration.⁴ In our patient, the fish bone that migrated was both of sharp and linear type and also horizontally-orientated.

A computed tomography (CT) scan is the primary tool of investigation because it can determine the size, location and orientation of FBs.³ More importantly the relationship of the FB with its surrounding structures.³ As in our case, the CT scan showed that the FB had pierced the wall of the common carotid

artery. Thus the surgical approach can be planned and the possible complication can be anticipated.

Advantages of CT imaging prior to neck exploration is that it gives a spatial impression of the FB orientation.³ The importance of having a 3-dimensional picture cannot be overemphasized and is crucial, especially when dealing with fish bones that has pierced vital structure as seen in our patient.

It is reported that FBs in the oesophagus is associated with a major complication rate of 7.3%. These include oesophageal perforation with associated peri-oesophagitis, abscess, mediastinitis or vascular complications such as aorto-oesophageal fistula, innominate Oesophageal fistula and carotid rupture which is fatal. The mortality rate of subsequent complications is 0.73%.⁶ Fortunately in this, none of the complications had occur either immediate post operatively or observed during follow up.

In conclusion, exploration of the neck for a migrated oesophageal FB is challenging. In our case, the fish bone had pierced the carotid artery wall which required meticulous dissection and care. A strong index of suspi-

cion is important especially when there are positive findings on neck radiograph but negative on rigid oesophagoscopy. FB penetration and migration can be diagnosed accurately with a CT scan of the neck which provides required input of the location, orientation and an overview 3-dimensional picture which is very much needed pre-operatively to facilitate the surgical exploration.

REFERENCES

- 1: Al-Sebeih K, Valvoda M, Sobeih A, Al-Sihan M. Perforating and migrating pharyngoesophageal foreign bodies: A series of 5 patients. *Ear Nose Throat J* 2006; 85:600-3.
- 2: Joshi AA, A Bradoo RA. A foreign body in the pharynx migrating through the internal jugular vein. *Am J Otolaryngol* 2003; 24:89-91.
- 3: Goh YH , Balakrishnan A. An unusual neck lump. *J Paediatr Surg* 2000; 35:1132-3.
- 4: Chee LW, Sethi DS. Diagnostic and therapeutic approach to migrating foreign bodies. *Ann Otol Rhinol Laryngol* 1999; 108:177-80.
- 5: Hung CW, Hung SC, Lee CJ, Lee WH, Wu KH. Risk factors for complications after a foreign body is retained in the esophagus. *J Emerg Med* 2012; 43:423-7.
- 6: Chen CY, Peng JP. Esophageal fish bone migration induced thyroid abscess: Case report and review of literature. *Am J Otolaryngol* 2011; 32:253-5.