

Tuberous sclerosis presenting as atypical aggressive retinal astrocytoma with proliferative retinopathy and vitreous haemorrhage

Pui Ling TANG and Mae-Lynn Catherine BASTION

Department of Ophthalmology, Faculty of Medicine, Universiti Kebangsaan Malaysia Medical Centre, Malaysia

ABSTRACT

A young lady with background features of tuberous sclerosis presented with sudden onset of floaters in the left eye. Initial visual acuity was 6/6 OU. Fundus examination showed an aggressive retinal astrocytoma with proliferative retinopathy and vitreous haemorrhage. Fundus fluorescein angiogram confirmed the presence of new vessels on the optic discs and on the astrocytoma. The patient received sectoral argon laser photocoagulation to the left eye. The vitreous haemorrhage and proliferative retinopathy subsequently subsided. The right eye remained quiescent throughout. The patient presented with a second episode of the left eye dense vitreous haemorrhage, with visual acuity of finger counting; necessitated a trans pars plana vitrectomy and vitreous clearance. Post vitrectomy, fundus showed telangiectatic vessels temporal to optic disc and inferotemporal arcades, with cystoids macular oedema. The patient received top up of pan retinal photocoagulation. Left BCVA remained 6/36, N18 after a decade of follow up.

Keywords: Aggressive retinal astrocytoma, proliferative retinopathy, tuberous sclerosis

INTRODUCTION

Ocular manifestation is part of tuberous sclerosis. Patients usually have unilateral or bilateral retinal astrocytic hamartomas. In most instances, these hamartomas remain benign. Aggressive retinal astrocytoma is a rare variant. The tumour may lead to complications including serous retinal detachment, neovas-

cular glaucoma and vitreous haemorrhage. Lifelong follow up are essential to monitor for progression of the astrocytomas and its significant complications.

CASE REPORT

A young lady in her twenties with background history of epilepsy presented with sudden onset of floaters affecting the left eye. There was no blurring of vision or flashes. No history of trauma prior to presentation. On general examination, the patient was noted to have

Correspondence author: TANG Pui Ling
Department of Ophthalmology, Level 9, Pusat Perubatan Universiti Kebangsaan Malaysia, Jalan Yaakob Latiff, 56000 Cheras, Kuala Lumpur, Malaysia.
Tel: +0060126300236, +0060391455982
E mail: tangpuiling84@gmail.com

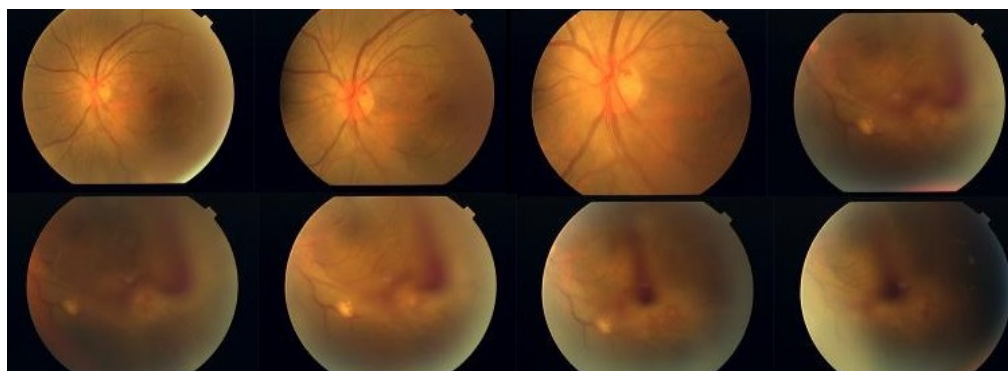

Fig. 1: Fundus photo of left eye showing the vascularised inferotemporal retinal astrocytoma with vitreous haemorrhage.

features suggestive of tuberous sclerosis which include adenoma sebaceum, hypomelanotic macules (ash leaf spots), shagreen patch and ungula fibromas. On ocular examination, the visual acuity was 6/6 OU with N5 near vision. The anterior segment examination was unremarkable with intraocular pressure (IOP) of 16mmHg bilaterally. Fundus examination of the left eye revealed a vascularised astrocytoma inferotemporally with vitreous haemorrhage inferiorly (Figure 1). There were also presence of new vessels at the optic disc and inferotemporal arcade vessels. The remaining astrocytomas looked benign. The right fundus revealed similar findings of benign looking astrocytomas (Figure 2). Based on the general physical and ocular findings, a diagnosis of aggressive retinal astrocytoma with proliferative retinopathy af-

fecting the left eye on the background of tuberous sclerosis was made.

Fundus fluorescein angiography (FFA) was done showing new vessels on the disc, leaky vessels and sparse capillary fall out areas over the area of astrocytoma inferotemporally (Figure 3). The right fundus showed areas of staining corresponding to the astrocytomas noted (Figure 4). The patient was subsequently treated with argon laser photocoagulation over the inferiortemporal quadrant. The new vessels and vitreous haemorrhage subsequently resolved within a month.

One month later, the patient presented again with a dense vitreous haemorrhage in the left eye. Left visual acuity was reduced to counting finger. The right eye remained

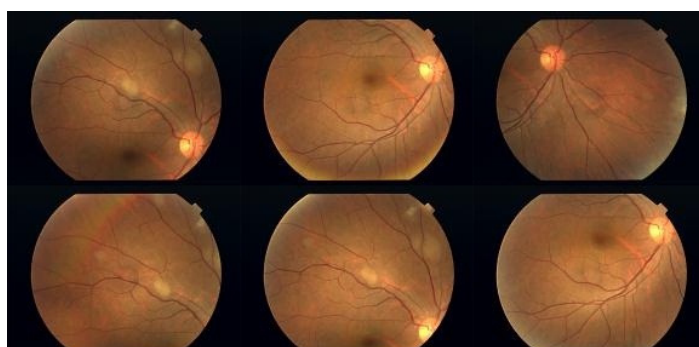


Fig. 2: Fundus photo of right eye showing multiple benign retinal astrocytomas.

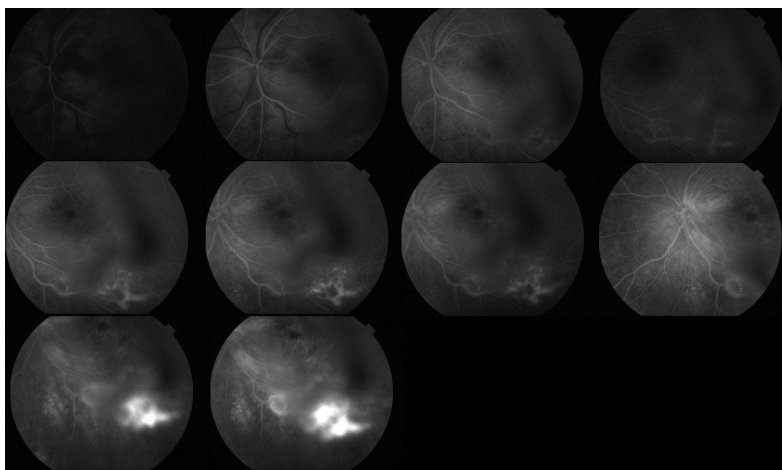


Fig. 3: Fundus fluorescein angiography (FFA) of the left eye showing presence of increased intensity and size of hyperfluorescence area over the new vessels and astrocytomas with time.

quiescent. The patient subsequently underwent pars plana vitrectomy (PPV) with vitreous washout and endolasers. Post operatively, fundal examination revealed a telangiectatic vessel temporal to the optic disc with cystoid macular oedema (Figure 5). A repeated FFA showed leakage from the telangiectatic vessel near the optic disc and confirmed the cystoid macula oedema (CMO). Patient was subjected for top up PRP along with topical ketorolac. The CMO was recalcitrant, along with development of nucleus sclerosis cataract. The patient opted for no further intervention. Her final best corrected

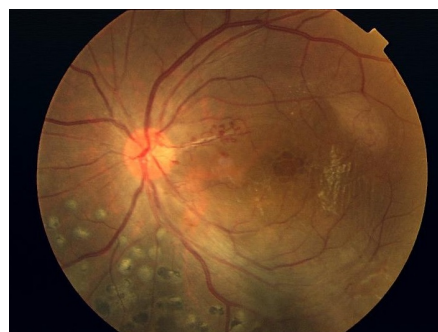

Fig. 5 : Fundus photo of left eye showing a telangiectatic vessel temporal to the optic disc with cystoid macular oedema post vitrectomy.

visual acuity (BCVA) was 6/36 OS, N18 while 6/6 OD. The patient has been on follow up for the past 11 years and the visual acuity and fundus findings remained the same.

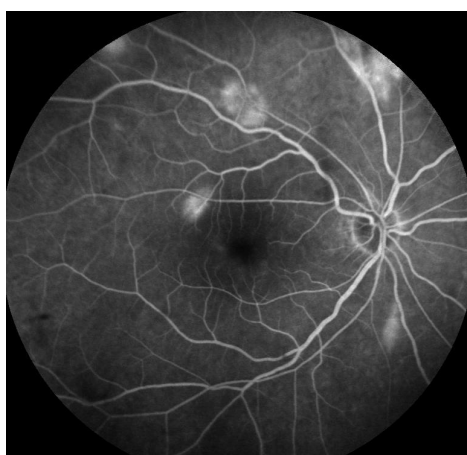

Fig. 4: Fundus fluorescein angiography (FFA) of the left eye showing presence of multiple staining hyperfluorescence areas corresponding to the benign retinal astrocytomas.

DISCUSSION

Tuberous sclerosis is an autosomal dominant systemic disorder characterised by the presence of hamartomas in multiple organs which include skin, brain, heart, kidneys and retina. Retinal astrocytomas are common ocular findings in tuberous sclerosis complex with up to 87% of patients having this lesion.¹ The lesions remain relatively static with little potential for aggressive behaviour.² Symptomatic changes are rarely seen in retinal astrocytomas in tuberous sclerosis.³ Shields *et al.*⁴ reported four patients with aggressive retinal

All had tuberous sclerosis complex and multiple tumours in the fundus. In all cases, the largest tumour near the optic disc showed progression. In our case, the aggressive tumour was also located near the optic disc, inferotemporally. According to Mennel *et al.*³, the benign retinal lesions can be classified into three morphological groups. Type 1 lesions are usually circular or oval shaped, relatively flat, semi-transparent, light grey with an average size of half disc diameter lying in the retinal nerve fibre layer (RNFL) without signs of calcification. The commonest retinal astrocytomas are of type 2 whereby they are multiple in number, calcified, well circumscribed, of variable sizes arising from the inner surface of retina and have been described to resemble the appearance of a mulberry. The third type has the combination features of type 1 and 2. Mennel *et al.*³ has found that the most symptomatic progressions were found in type 1 astrocytomas (75%) whereas only 25% of type 2 lesions became symptomatic. The symptomatic alterations include enlarging tumours with exudates, macular oedema, serous retinal detachment, vitreous haemorrhage and secondary rubeosis iridis with increased intraocular pressure. In our case, the retinal astrocytomas were of type 1 which showed symptomatic progression to proliferative retinopathy and vitreous haemorrhage.

It has been reported that hamartomas associated with tuberous sclerosis involving multiple organs are highly angiogenic and may express Vascular Endothelial Growth Factor (VEGF).⁵⁻⁶ Tomida *et al.*² showed the presence of VEGF in both the retinal astrocytoma and epiretinal membrane in the eye where vitrectomy was done for persistent

vitreous haemorrhage. Several treatment modalities have been used in treating the proliferative features of retinal astrocytomas which include argon laser photocoagulation, photodynamic therapies, intravitreal bevacizumab and vitrectomy. In our case, post argon laser photocoagulation and vitrectomy, macular oedema was recalcitrant and was the most likely cause of her poor vision besides the nucleus sclerosis cataract. Although the telangiectatic vessels near the optic disc were still present, it progressively became attenuated and did not show signs of leakage. All the remaining astrocytomas remained benign and quiescent. As patient had been followed up for 12 years to date, there were no signs of rubeosis iridis or secondary glaucoma seen in this patient.

The learning point of this case is that the usually benign retinal astrocytomas in tuberous sclerosis complex can take an aggressive course over years. Thus, these patients should be followed up lifelong to watch out for the progression of the retinal astrocytomas and its possible complications such as vitreous haemorrhage, rubeosis iridis with secondary glaucomas and exudative retinal detachment.

REFERENCES

- 1: Roach ES, Sparagana SP. Diagnosis of tuberous sclerosis complex. *J Child Neurol.* 2004; 19:643-9.
- 2: Tomida M, Mitamura Y, Katome T, Eguchi H, Naito T, Harada T. Aggressive retinal astrocytoma associated with tuberous sclerosis. *Clin Ophthalmol.* 2012; 6:715-20.
- 3: Mennel S, Meyer CH, Peter S, Schmidt JC, Kroll P. Current treatment modalities for exudative retinal hamartomas secondary to tuberous sclerosis: review of literature. *Acta Ophthalmol Scand.* 2007; 85:127-32.

4: Shields JA, Eagle RC, Jr Shields CL, Marr BP. Aggressive retinal astrocytomas in 4 patients with tuberous sclerosis complex. Arch Ophthalmol. 2005; 123:856-63.

5: Saito W, Kase S, Ohgami K, Mori S, Ohno S. Intravitreal anti-vascular endothelial growth factor therapy with bevacizumab for tuberous sclerosis

with macular oedema. Acta Ophthalmol. 2010; 88:377-80.

6: Arbiser JL, Brat D, Hunter S, et al. Tuberous sclerosis associated lesions of the kidney, brain, and skin are angiogenic neoplasms. J Am Acad Dermatol. 2002; 46:376-80.