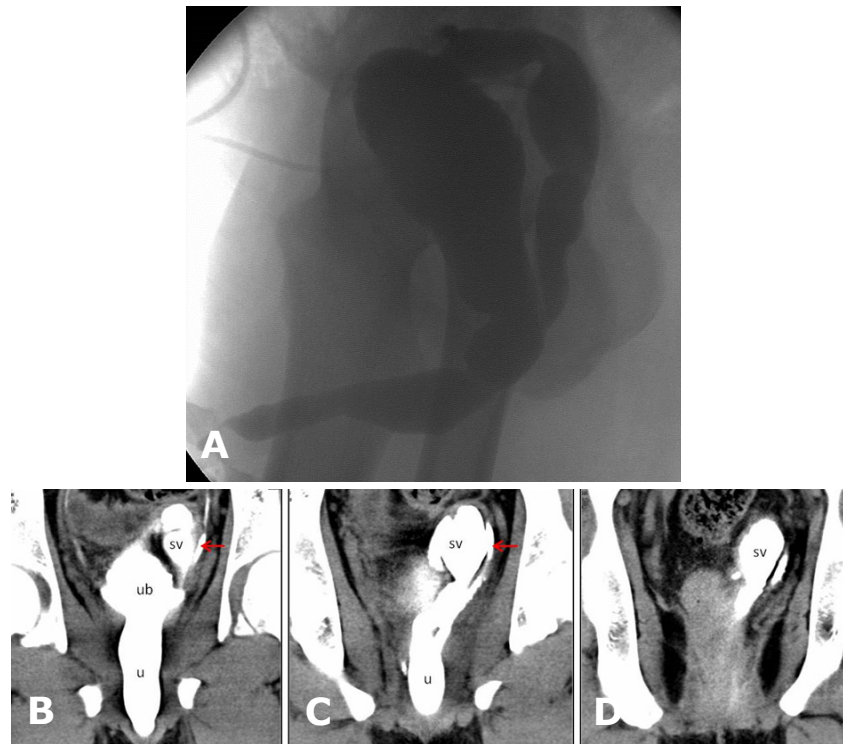


Mohd Nazli KAMARULZAMAN, Siti Kamariah CHE MOHAMAD, Hamid GHAZALI



A 19-year-old boy who had underwent hypospadias repair 10 years ago presented with acute urinary retention. Attempt to insert a continuous bladder drainage fail due to a high urethral stricture. Thus supra-pubic catheter was inserted. On further questioning patient claimed that he had experience symptoms of poor urinary flow with incomplete voiding for a few years. The imaging result showed presence of distal urethral stricture (Figure 1) with other uro-genital tract abnormalities (**Panels A, B, C and D**)

What is the diagnosis?

Answer: refer to page 64

Correspondence author: MD KAMARULZAMAN
Department of Surgery, Kulliyah of Medicine
International Islamic University Malaysia
Jalan Hospital Campus, 25100 Kuantan, Pahang,
Malaysia
E mail: nazlikamarulzaman@gmail.com