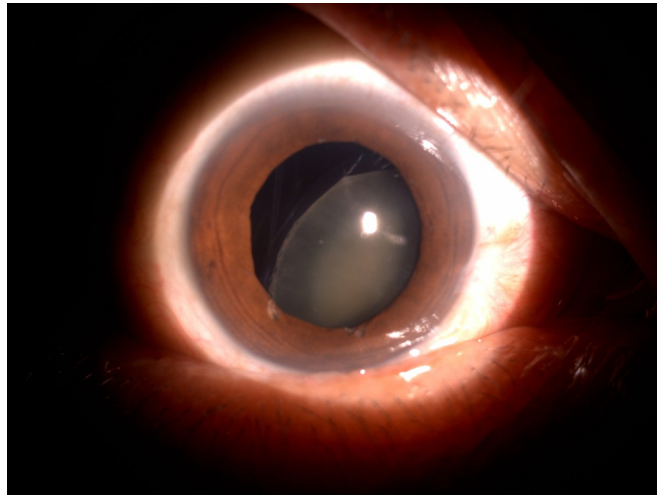


**Nadir ALI**



A 58-year-old man presented with blurred vision in the right eye that was associated with pain and redness for two weeks prior to presentation. He gave history of being punched on the right eye during a fight two years ago. His visual acuity was 'Hand Movement' in the right eye and 6/7.5 in the left eye. The intraocular pressure was 40 mmHg in the right eye and 14 mmHg in the left eye. His anterior segment examination is shown above (**Panel**).

**What is the diagnosis?**

**Answer:** refer to page 63

**Correspondence author:** Nadir ALI  
Eye Centre, RIPAS Hospital, Bandar Seri Begawan  
BA 1710, Brunei Darussalam.  
Tel: +673-8223690  
E mail: nadiramali@hotmail.com