

# Snake envenomation: An unusual cause of hypopituitarism

Suresh P RAJASEKARAN, Senthil KUMAR. R, Vijayalakshmi BALACHANDRAN  
Department of Endocrinology, PSG Institute Of Medical Sciences and Research,  
Tamil Nadu, India

## ABSTRACT

Snake bites are very frequent in India especially in rural areas. Cobra and viper bites can cause neurotoxicity and haemotoxicity respectively in humans. Viper bite causes acute hemorrhagic manifestations and rarely causes acute or chronic hypopituitarism. Hypopituitarism can be partial or complete, deficient of one or more pituitary hormones. This case report highlights the importance of identifying hypopituitarism due to snake bite as it can be a delayed manifestation.

**Keywords:** Hypopituitarism, hyponatraemia, snake bite

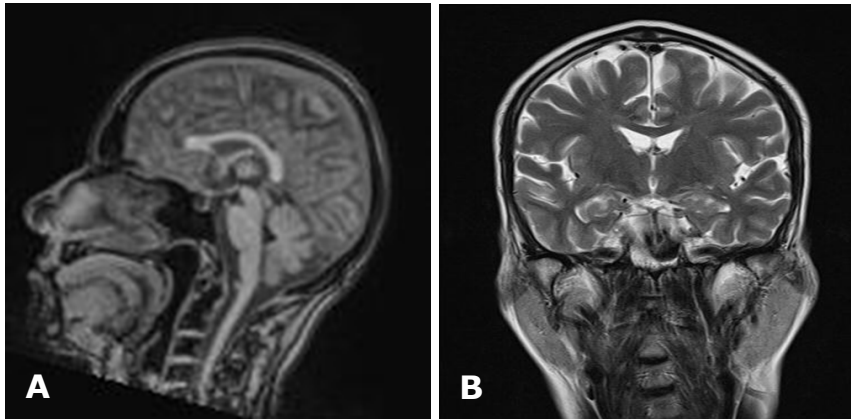
## INTRODUCTION

Snake bites are very frequent in the underdeveloped and developing countries including India, especially in rural areas. Most are often minor and never present to health institutions. However, snake bite can be serious and lethal. Certain species of snake are well known to be associated with significant complications. Cobra and viper bites can cause neurotoxicity and haemotoxicity respectively in humans. Viper bite causes acute haemorrhagic manifestations and rarely causes acute or chronic hypopituitarism. Hypopituitarism can be partial or complete resulting in deficiency of one or more pituitary hormones. This case report highlights the importance of identifying hypopituitarism due to snake bite as it can be a delayed manifestation.

**Correspondence author:** Suresh RAJASEKARAN  
PSG hospitals  
Peelamedu  
Coimbatore, Tamil Nadu, India.  
0422-2570170 -5354  
E mail: Docsuresh1974@yahoo.co.in

## CASE REPORT

A 53-year-old man presented with recurrent episodes of nausea, vomiting and drowsiness of recent onset. He was admitted under the Gastroenterology Service for evaluation. He was otherwise well apart from non specific intermittent weakness. His upper duodenoscopy and ultrasound abdomen were normal. Biochemical investigation showed hyponatraemia. Even after sodium replacements, he had persistent hyponatraemia and there was no improvement in clinical symptoms. On clinical examination he had paper money skin, absence of facial hair and secondary sexual characters. The testicular volume measured approximately 2mL bilaterally. So he was referred for endocrine evaluation. Hormonal investigations showed normal thyroid stimulating hormone with low free thyroxine. Early morning serum cortisol, stimulated cortisol and testosterone were all very low, sugges-



**Figs. 1:** A) Sagittal section of the MRI showing the pituitary sella filled with CSF and no posterior pituitary bright spot, and B) Coronal section showing an empty sella.

tive of hypopituitarism.

A magnetic resonance imaging (MRI) of the pituitary was done which revealed a normal sella filled with cerebro spinal fluid (CSF) and an atrophic pituitary tissue in the posterior aspect of pituitary fossa and absent posterior pituitary bright spot (Figures 1). On revisiting the history, it came to light that he had a snake bite 15 years previously following which he has had haemorrhagic manifestations leading to acute kidney injury requiring haemodialysis. Few years later he noticed lethargy, general weakness, sleepiness and loss of libido. He also gave history of decreased frequency of shaving. Based on this information, a clinical diagnosis of panhypopituitarism caused by pituitary haemorrhage due to snake bite was made. As there was no previous history of visual field defects/headache (suggestive of pituitary tumours/apoplexy), head injury or radiotherapy, we excluded other possible causes of hypopituitarism. He was commenced on intravenous hydrocortisone and sodium levels normalised. His symptom gradually improved and was then changed over to oral steroids. Thyroid

hormone and testosterone replacements were commenced latter. He came for review after two months where there was a remarkable improvement in his clinical symptoms and he is on regular follow up till now.

## DISCUSSION

Hypopituitarism is defined as impaired synthesis of one or more anterior pituitary hormones. The aetiology of hypopituitarism is divided into acquired and congenital causes. Inherited pituitary deficiency is due to mutation in the transcription factor involved in the development of pituitary gland. This includes single gene mutation in PROP 1, PIT X1, PIT X2, HES X 1 and LHX3 which may result in isolated hypopituitarism or deficiency of one or more pituitary hormones.<sup>1</sup> In congenital hypopituitarism, patient may present with short stature and delayed puberty. The acquired causes are pituitary tumors, pituitary apoplexy, head trauma, pituitary surgeries and radiation. In females, post partum pituitary necrosis is one of the most important cause for hypopituitarism. Clinical spectrum of presentation depends upon the severity of involvement and the rapidity of onset.

Snake bites are very common in South Asia and can sometimes be fatal. Hypopituitarism caused by snake bite is often a missed clinical entity and high degree of clinical suspicion is required to diagnose this condition. Furthermore, the manifestations of hypopituitarism may not become obvious until later, that can be months to years after the initial events. Patient may often present with nonspecific symptoms like nausea, vomiting, lethargy and weight loss due to cortisol deficiency. Hyponatraemia is one of the commonest presentation of hypopituitarism.

Hypopituitarism due to snake bite was first reported in three adults from South India in 1976 by Eapen *et al.*<sup>2</sup> Among the cases reported from India and Burma, 73% of the snake bites have been attributed to Russell's viper species (Figure 2). Russell's viper is more widely distributed in Sri Lanka, Bhutan and Bangladesh. Among the snake bites, Russell's viper venom causes localised haemorrhage, acute kidney injury and micro vascular thrombin deposition leading to hemorrhagic infarction of the pituitary gland causing acute or chronic hypopituitarism.<sup>3,4</sup> Autopsy study of patients presenting with acute hypopituitarism in Burma showed focal haemorrhagic micro vascular deposits which may be the cause for hypopituitarism in patients who have had snake bites.<sup>6</sup> In an observational study of 96 patients with vasculotoxic snake bite, 9.37% of the patients showed evidence of hypopituitarism.

Posterior pituitary involvement is less common and only four cases have been reported from south India.<sup>5</sup> A study in Burma showed three out of nine patients developed acute pituitary insufficiency. The time interval



between the snake bite and the onset of hypopituitarism ranges from six months to 20 yrs.<sup>7,8</sup> An unpublished study from Sri Lanka showed no features of acute cortical insufficiency among 336 patients presenting with snake bites.

In conclusion, hypopituitarism after a snake bite is rare and is often insidious in onset. Diagnosis is often delayed especially if not suspected. Hence this entity should be thought of in patients who have had snake bite and hormonal evaluation should be undertaken if clinically appropriate.

#### REFERENCES

- 1: Alatzoglou KS, Dattani MT. Genetic forms of hypopituitarism and their manifestation in the neonatal period, 2009; 85:705-12.
- 2: Eapen CK, Chandy N, Kochuovarkey KL, et al. Unusual complication of snake bite hypopituitarism after viper bites. In: Ohasaka A, Hayashi K, Sawai Y, eds. Animal, plant and microbial toxins, New York, NY, plenum press, 1976; 467-73.
- 3: Proby C, Aung T, Win T, et al. Immediate and long term effects on hormone levels following bites by the Burmese Russell's Viper. Q J Med. 1990; 399-411.
- 4: Than T, Francis N, Swe TN, et al. Contribution of focal hemorrhage and micro vascular fibrin deposi-

tion to fatal envenoming by Russell's viper (*Viper russelli siamensis*) in Burma. *Acta Trop.* 1989; 46: 23-38.

**5:** Gupta UC, Grag OP, Katharia ML. central diabetes insipidus due to viper bite. *J Asso Physicians India.* 1991;39:579-80.

**6:** Than T, Han KE, Hutton RA, et al. Contribution of focal haemorrhage and micro vascular fibrin deposi-

tion to fatal envenoming by Russell's viper (*Viper russelli siamensis*) in Burma. *Acta Trop.* 1989;46:23-38.

**7:** James E, Kelkar PN. Hypopituitarism after viperine bite. *J Asso Physicians India.* 2001;49:937-8.

**8:** Majeed PA, Thomas Z. Panhypopituitarism as a sequelae to snake venom poisoning – a report of six cases, In: *Abstracts of Association of Physicians, India, Conference, Madhura, 1987.*

---