

# Bilateral xanthogranulomatous oophoritis with multiple liver abscesses secondary to Actinomycosis

Mohammad HANAFIAH,<sup>1,3</sup> Benny YOUNG,<sup>2</sup> LOW Soo Fin,<sup>3</sup> Bushra JOHARI<sup>1</sup>

<sup>1</sup> Medical Imaging Department, Clinical Training Centre, Universiti Teknologi MARA, Selangor, Malaysia,

<sup>2</sup> Faculty of Medical and Health Science, UNIMAS, Sarawak, Malaysia

<sup>3</sup> Department of Radiology, Universiti Kebangsaan Malaysia Medical Centre, Kuala Lumpur, Malaysia

## ABSTRACT

Pelvic inflammatory disease usually results from ascending cervical or vaginal infection and is often polymicrobial, with usually anaerobic microbial. Xanthogranuloma is a specific type of manifestation of an inflammatory response that may affect various organs usually in association with chronic infection. Xanthogranulomatous oophoritis is a very rare entity and is refers to such inflammatory response affecting the ovaries, frequently complicating a chronic pelvic inflammatory disease (PID). We report a case of bilateral xanthogranulomatous oophoritis secondary to actinomycosis that was associated with multiple liver abscesses, and described the radiological findings.

**Keywords:** Xanthogranuloma, pelvic inflammatory disease, infection, abscesses

## INTRODUCTION

Pelvic inflammatory disease usually results from ascending cervical or vaginal infection. The culture often reveals a polymicrobial infection with a preponderance of anaerobes. The predominant organisms are *Escherichia coli*, *Bacteroides fragilis*, aerobic *Streptococcus*, *Peptococcus*, and *Peptostreptococcus*.<sup>1</sup>

Xanthogranuloma is a specific type of manifestation of an inflammatory response that may affect various organs usually in as-

association with chronic infection. Xanthogranulomatous oophoritis is a very rare entity and is refers to such inflammatory response affecting the ovaries, frequently complicating a chronic pelvic inflammatory disease (PID). Actinomycosis, a chronic suppurative infection by *Actinomyces israeli*, is a rare cause of pelvic inflammatory disease.<sup>1</sup> In addition, actinomycosis is frequently misdiagnosed as malignancy on cross sectional imaging due to its predominantly solid appearance.

<sup>1</sup> Here, we report a case of bilateral xanthogranulomatous oophoritis secondary to actinomycosis that was associated with multiple liver abscesses, and described the radio-

**Correspondence author:** Bushra JOHARI  
Faculty of Medicine, Universiti Teknologi MARA,  
47000 Sungai Buloh, Selangor, Malaysia.  
Tel: +6012-3729495 (mobile), +603-61265164,  
E mail: drbushra@salam.uitm.edu.my

logical findings. Understanding the characteristic imaging findings of this entity is very important to allow appropriate management.

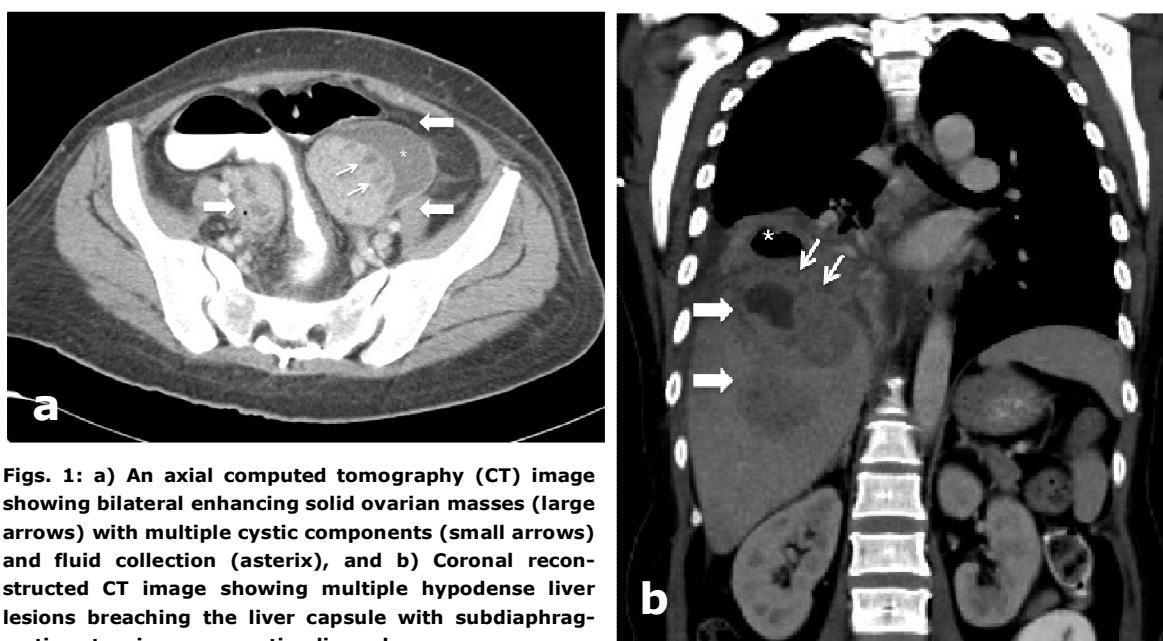
## CASE REPORT

A 48-year-old para <sup>1+2</sup> female patient presented with a 3-month-history of lower abdominal pain, fever, weight loss, loss of appetite and diarrhoea. There were no significant previous medical or surgical histories. She had an active sexual life and had been using intrauterine contraceptive devices (IUCD) for 18 years.

Blood pressure, pulse rate and temperature at presentation were 128/80, 76 beats per minute and 34.7°C respectively. Abdominal examination revealed a non-tender mass arising from the left hemi-pelvis. Vaginal speculum examination showed a normal cervix with IUCD string at its external os. Minimal whitish thrush was noted on the vaginal wall. The IUCD was removed.

Cervical smear showed colonies of bacteria, which morphologically was consistent with Actinomyces. Further evaluation with endometrial sampling showed mainly mixed inflammatory cells with actinomycete colonies densely infiltrated the underlying stroma. No adequate endometrial tissue was sampled and there were only tiny fragments of cervical tissue with squamous epithelium seen. No malignant cells were detected in this limited sample. Laboratory investigations revealed low haemoglobin of 9.6g/dL (Normal 12.0 to 16.0), raised White Cell Count of  $20.2 \times 10^9/L$  (4.0 to 11.0) with predominantly neutrophil cells and raised C-Reactive Protein of 11.60mg/dl (<10.0). The tumour markers of CA-125, CEA and AFP were 12 U/ml (<35); 1.6 ng/mL (<5.0) and 2.84 ng/mL (<10.0) respectively.

Contrasted computed tomography (CT) scan of the thorax, abdomen and pelvis was performed and revealed bilateral ovarian masses and multiple hypodense liver lesions.



**Figs. 1:** a) An axial computed tomography (CT) image showing bilateral enhancing solid ovarian masses (large arrows) with multiple cystic components (small arrows) and fluid collection (asterix), and b) Coronal reconstructed CT image showing multiple hypodense liver lesions breaching the liver capsule with subdiaphragmatic extension representing liver abscesses.

The ovarian masses showed enhancing solid appearance with multiple cystic components (Figure 1a). There was no calcification or fat within the masses. The largest liver lesion in segment 8 of the liver demonstrated central liquefaction or necrosis (Figure 1b). In addition, it had breached the overlying liver capsule, forming a sub-diaphragmatic extension of the lesion (Figure 1b). The overlying diaphragm was elevated and the ipsilateral lung base showed reactive consolidation with minimal pleural effusion. No intra-abdominal or pelvic lymphadenopathy was seen.

Samples taken from one of the liver lesions via trans-abdominal biopsy and pleural tapping revealed inflammatory processes without evidence of malignant cells. AFB staining and culture were negative from these specimens. In view of the complex and solid-looking ovarian masses with some degree of suspicion of potential underlying malignancy that cannot be entirely excluded, she underwent exploratory laparotomy and a total abdominal hysterectomy-salpingo-oophorectomy. Intra-operatively, the complex ovarian masses demonstrated multiloculated fluid with solid components. The right ovarian mass had thick capsule, which was densely adhered to the ipsilateral ovarian fossa and the Pouch of Douglas. Both of the fallopian tubes were embedded in the adnexal complex masses.

Macroscopically, the ovarian masses had firm consistency and the cut sections revealed cystic and solid areas. The cysts were filled with gelatinous material and the solid components were made of both greyish and yellowish materials, a mixture of necrosis and xanthogranulomata. Histopathological examination of the ovarian masses showed exten-

sive lobular granulomatous fibrous tissue formation with scattered microabscesses containing clusters of sulphur granules, which exhibited central tangled branching filaments. There were abundant foamy histiocytes, haemosiderin-laden-macrophages and lymphoplasmacytic infiltration demonstrated within the ovarian stroma. However, no atypia, dysplasia or malignancy was seen. The culture came back as *Actinomyces* species, which confirmed the final diagnosis of bilateral xanthogranulomatous oophoritis caused by an underlying infection of actinomycosis.

The patient received and completed a course of antimicrobial therapy that consisted of oral Clarithromycin 500mg twice daily and intravenous Augmentin 1g once daily. The repeat CT scan three months later showed marked reduction of the liver and the sub-diaphragmatic lesions. No recurrence of the pelvic lesions.

## DISCUSSION

Actinomycosis is a chronic suppurative infection by *Actinomyces israelii*, characterised by formation of multiple abscesses and abundant granulation tissue. Pelvic actinomycosis is highly associated with ascending infection from the female genital tract, and the use of IUCDs is thought to increase the prevalence. The presence of sulfur granules as well as multiple Gram-positive branching hyphae at pathologic examination is important in diagnosing this infection<sup>1</sup> as demonstrated by the present case.

Ovarian actinomycosis is frequently misdiagnosed as ovarian malignancy owing to its unusual appearance in cross-sectional imaging.<sup>1</sup> It usually appears as a predominantly

solid or a solid and cystic mass in the adnexal region. The outline of the lesion may be well or ill-defined depending on the stage of the infection, with an ill-defined margin tend to be seen in chronic stage.<sup>1</sup> A linear, solid, well-enhancing lesion extending directly from the mass is a characteristic CT and MR imaging finding.<sup>1</sup> Occasionally, these inflammatory extensions form masses in the perirectal spaces or cul-de-sac, mimicking seeding masses from ovarian malignancies. The presence of small rim-enhancing lesions representing small abscesses in the solid part of the mass is also a suggestive feature.<sup>1</sup> Less commonly, tubo-ovarian actinomycosis appears as thick-walled cystic masses, and the differentiation from the usual tubo-ovarian abscesses is very difficult or impossible. Typically, actinomycosis has an invasive nature owing to its proteolytic enzymes, showing spread by direct extension across the tissue planes with the formation of multiples abscesses, tracts and sinuses.<sup>1</sup> It may invade the blood stream and seed to other organs haematogenously. In the present case, the tubo-ovarian actinomycosis exhibited the characteristic appearance of predominantly solid enhancing masses with multiple small hypodense lesions representing micro-abscesses within them. There was also a haematogenous spread of infection to the liver as multiple abscesses with demonstration of its typical invasive nature.

Xanthogranulomatous inflammation is a type of chronic inflammation characterised by destructive infiltration of the affected tissue or organ with focal or sheets of foamy macrophages and other accompanying chronic inflammatory cells such as lymphocytes, plasma cells, and polymorphonuclear leuko-

cytes.<sup>2,3</sup> This type of inflammation is a well-established histopathological entity in the gallbladder and kidney.<sup>4</sup> On the other hand, xanthogranulomatous inflammation involving the female genital tract is unusual and mainly unilateral if it involves the ovary or fallopian tube.<sup>3</sup> The clinical presentations include non-specific lower abdominal pain, fever, menorrhagia, or vaginal bleeding.<sup>3</sup> Examination often reveals adnexal tenderness and pelvic mass while the laboratory tests usually show raised white cell counts or other inflammatory markers like CRP and ESR.<sup>3</sup> However, symptoms can be vague or even absent in chronic stage making differentiation from ovarian malignancies very challenging.

The exact pathogenesis of xanthogranulomatous inflammation is not clearly understood. Pelvic endometriosis, PID, intrauterine contraceptive device (IUCD), ineffective antibiotic therapy, abnormality in lipid metabolism and chemotherapy have all been linked to this uncommon form of inflammatory response.<sup>2</sup> A combination of these factors may be responsible. Haemorrhage, microorganism colonisation by IUCD and chemotherapy for instance may predispose to infection and tissue necrosis, followed by release of cholesterol and other lipids, which subsequently phagocytised by the macrophages forming accumulation of foam cells. However, the accumulation of large amount of foam cells containing lipids is hard to be elucidated by the theory of infection alone. An inadequate control of bacteria multiplication owing to incomplete or inappropriate antibiotics that were applied in the early phase of the infection, coupled with possible underlying lipid metabolic disorder, may promote more lipid deposition in the affected region and increase the chance of this

kind to inflammatory response to occur.<sup>3</sup> This is a possible explanation as to why this condition is commonly observed in patients with history of long-standing or recurrent pelvic inflammatory disease. From a cross sectional imaging standpoint, the appearance of xanthogranulomatous oophoritis, not pertaining to any underlying pathogenic cause, are variable and usually presented as mixed solid and cystic lesions, again mimicking malignancy.<sup>1</sup>

In conclusion, ovarian actinomycosis with underlying xanthogranulomatous inflammation is a rare condition and a mimicker of an ovarian malignancy. Therefore, knowledge of this entity is important in interpreting cross-sectional images of ovarian masses, especially with vague and non-specific clinical presentation. Although cross sectional imag-

ing findings are inconclusive in many cases, some characteristic findings may help one make the correct diagnosis and treat the patients appropriately.

#### REFERENCES

- 1:** Kim SH, Kim SH, Yang DM, Kim KA. Unusual causes of tubo-ovarian abscess: CT and MR Imaging Findings. *RadioGraphics* 2004; 24:1575-89.
- 2:** Yener N, Ilter E, Midi A. Xanthogranulomatous salpingitis as a rare pathologic aspect of chronic active pelvic inflammatory disease. *Indian J Pathol Microbiol.* 2011; 54:141-3.
- 3:** Zhang XS, Dong HY, Zhang LL, Desouki MM, Zhao C. Xanthogranulomatous inflammation of the female genital tract: report of three cases. *J Cancer.* 2012; 3:100-6.
- 4:** Jung SE, Lee JM, Lee KY, Han KT, Hahn ST. Xanthogranulomatous oophoritis: MR imaging findings with pathologic correlation. *AJR* 2002; 178:749-51.