

# Accessory forearm flexor muscle: a rare case report

Lydia S. QUADROS, Pangsatabam Anjali ROY, Antony Sylan D'SOUZA  
Department of Anatomy, Kasturba Medical College, Manipal University, Madhav Nagar,  
Manipal, Karnataka, India

## ABSTRACT

Accessory muscles in the forearm region have been reported widely. In the present case, an accessory flexor muscle was observed in the front of the left forearm. The fibres extended from the tendon of flexor carpi radialis to flexor digitorum superficialis. A few lower fibres formed a tendon which inserted into the radial side of the flexor digitorum superficialis. It was innervated by the median nerve. The accessory muscle described here could increase the range and power of movement of the forearm and the palm. This type of variation is noteworthy in conditions like pressure neuritis.

**Keywords:** Accessory muscle, forearm, flexor carpi radialis, flexor digitorum superficialis, pressure neuritis

## INTRODUCTION

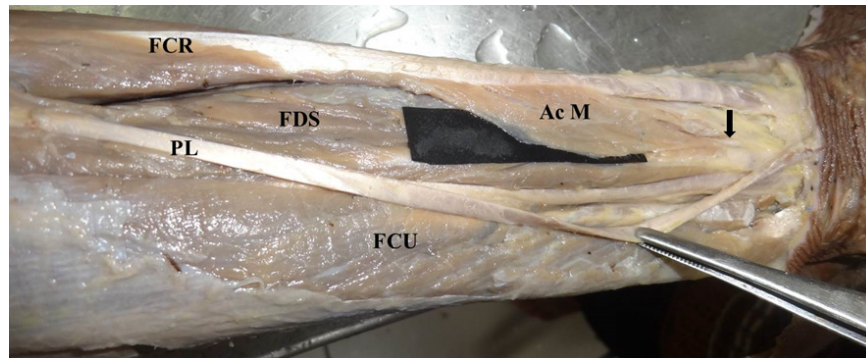
The forearm flexors muscles are commonly arranged in two strata, superficial and deep. Accessory forearm flexor muscles of the deep stratum are widely reported.<sup>1-3</sup> Gantzer in 1813 described two accessory forearm flexor muscles which took origin from the deep forearm flexor muscles and inserted either into the Flexor pollicis longus or Flexor digitorum profundus. These accessory muscles are called Gantzer's muscles. Many authors have reported the presence of Gantzer's muscles with variability in their insertion. In the variation reported in the present case, the muscle

fibres took origin from the tendon of flexor carpi radialis and inserted into the tendon of flexor digitorum superficialis. This is a very rare finding.

## CASE REPORT

The left upper limb of the formalin fixed 65-year-old male cadaver was dissected during the routine dissection class for the undergraduate students. The dissection was carried out as per the instructions given in the Cunningham's manual of practical anatomy.<sup>4</sup> The variation was noted and photographed. The muscle fibres took origin from the tendon of flexor carpi radialis and inserted to the tendon of flexor digitorum superficialis. A few lower fibres formed a separate tendon and inserted into the tendon of flexor digitorum superficial-

**Correspondence author:** Lydia S. QUADROS  
Department of Anatomy, Kasturba Medical College,  
Manipal University, Madhav Nagar, Manipal,  
Karnataka, India – 576104  
Tel: (0820) 2922327. E mail: lidibudy@gmail.com



**Fig. 1:** Left upper limb showing FCR – Flexor carpi radialis, FDS – Flexor digitorum superficialis, PL – Palmaris longus, FCU – Flexor carpi ulnaris, AcM – Accessory forearm flexor muscle, Arrow – tendon of AcM.

is on its radial side. The width of the muscle fibres was 4.9 cms on the flexor carpi radialis and 4.5 cms on the flexor digitorum superficialis. The length of the tendon was three cms (Figure 1).

## DISCUSSION

Different anomalies of the accessory flexor muscles of forearm such as Gantzer’s muscles have been described. In most cases, the muscles go unnoticed as they are usually asymptomatic. However they may cause functional deficits by compressing the neurovascular structures. Accessory forearm flexors, when present may cause compression of the anterior interosseous artery leading to vascular tearing of the distal part of the forearm. The tendon of the accessory forearm flexors would get inserted into the palm wherein, the tendon would likely pass superficial or deep to the flexor retinaculum. If the tendon passed deep to the flexor retinaculum, there would be crowding of the tendons which would be a cause carpal tunnel syndrome. In the present case, the tendon inserted into the tendon of flexor digitorum superficialis and this would not have led to the carpal tunnel syndrome.

But the muscle fibres would exert pressure onto the underlying artery and nerve leading to numbness of the distal part of the upper extremity.

Accessory head of flexor pollicis longus is of significant importance in anterior interosseous nerve syndrome.<sup>5</sup> In a study conducted on 200 upper limbs, additional heads of flexor pollicis longus and accessory palmaris longus was observed in two upper limbs. In the present case no such finding was observed.<sup>3</sup>

Absence of palmaris longus is a known fact. In the present case, palmaris longus with a very long tendon was present. Gantzer’s muscles have been reported by many previous authors.<sup>1, 2</sup> In the present case, there were no additional muscle bellies.

The flexor muscles of the forearm develop from the flexor mass, which subsequently divide into two layers, superficial and deep. The superficial layer gives rise to pronator teres, flexor carpi radialis, palmaris longus, flexor digitorum superficialis and flexor

carpi ulnaris. The present variation might have occurred due to improper cleavage of the superficial flexor mass during development. <sup>6</sup> The accessory muscle may provide additional range and power of flexion. However, this is likely to be insignificant.

In conclusion, knowledge of such variations is of utmost importance to the surgeons in performing the surgery and for the radiologists in the interpretation of the radiographs. This type of variation is also of academic interest for the anatomists.

#### REFERENCES

- 1:** Nayak SR, Ramanathan L, Prabhu LV, Raju S. Additional flexor muscles of the forearm: a case report and clinical significance. *Med J.* 2007; 48:e231-e3.
  - 2:** Vollala VR, Nagabhooshana S, Bhat SM, Potu BK, Rakesh V. Multiple accessory structures in the upper limb of a single cadaver. *Singapore Med J.* 2008; 49:e254.
  - 3:** Sembian U, Srimathi T, Muhil M, Nalina Kumari SD, Subramanian T. A study of the accessory muscles in the flexor muscles in the flexor compartment of the forearm. *J Clin Diagn Res.* 2012; 6:564-7.
  - 4:** Romanes GJ, Upper and lower limbs. In: Cunningham's Manual of Practical Anatomy. 15th ed. New York: Oxford University Press. 1993:74.
  - 5:** Bhagath KP, Gorantla RV, Thejodhar P, et al. Accessory head of flexor pollicis longus and its significance in anterior interosseous nerve syndrome: Case report and review. *Int J Morphol.* 2007; 25:911-4.
  - 6:** Lewis WH. The development of the muscular system. In: Keibel F, Mall FP eds, *Manual of Human Embryology*, Philadelphia, J.B.Lipincott. 1910:492-3.
-