

# Musculoskeletal manifestations with subtle haematological and radiological abnormalities in childhood acute lymphoblastic leukaemia

SHALIZA NS, FAIZAL A HAMZAH, H EMBONG

Department of Emergency Medicine, Faculty of Medicine, Universiti Kebangsaan Malaysia Medical Centre, Kuala Lumpur, Malaysia

## ABSTRACT

Musculoskeletal manifestations may be the only apparent abnormality at the onset of disease in childhood acute lymphoblastic leukaemia (ALL). These clinical presentations are often misdiagnosed as diverse forms of orthopaedic and rheumatologic disease, therefore contributes to delay in diagnosis and treatment. We report the case of a 3-year-old child who was diagnosed with ALL after recurrent visits with persistent painful left ankle swelling. Initial haematological and radiological findings revealed subtle abnormalities. A bone marrow aspiration confirmed the diagnosis of precursor-B ALL. This case highlights that acute leukemia needs to be considered in the differential diagnosis in any child presenting with musculoskeletal pain and unexplained lymphocytosis and neutropenia. Radiological abnormalities include diffuse osteopaenia, radiolucent metaphyseal bands, osteolytic lesion and sclerotic lesions which may raise the suspicion of acute leukemia, but are not always pathognomonic. Delay in diagnosis and treatment may have a deleterious impact on prognosis.

**Keywords:** Childhood leukemia, lymphocytosis, cellulitis, atypical manifestations

## INTRODUCTION

Acute lymphoblastic leukaemia (ALL) is the most common subtype of childhood leukaemia, representing 80% of childhood malignancies. <sup>1</sup> ALL is one form of acute leukaemia in which musculoskeletal manifestations (with or without haematological and radiological abnormalities) is commonly reported. <sup>2, 3</sup> De-

lay in diagnosis and initiation of treatment occurs when these manifestations are mistaken for other orthopaedic and rheumatologic disease such as rheumatic fever, juvenile idiopathic arthritis, reactive arthritis, osteomyelitis and septic arthritis. <sup>1</sup> Moreover, diagnostic pitfalls arise when the haematologic profile and radiographic changes are subtle or even normal at the initial presentation. We report the case of a child with ALL who presented with persistent left ankle pain that erroneous-

**Correspondence author:** Nurul Shaliza Shamsudin, Department of Emergency Medicine, Faculty of Medicine, Universiti Kebangsaan Malaysia Medical Centre, Jalan Yaacob Latiff, Bandar Tun Razak, 56000 Cheras Kuala Lumpur, Malaysia.  
Tel: +603-91455491. E mail: shalit282@yahoo.com

ly diagnosed and treated as cellulitis and septic arthritis.

### CASE REPORT

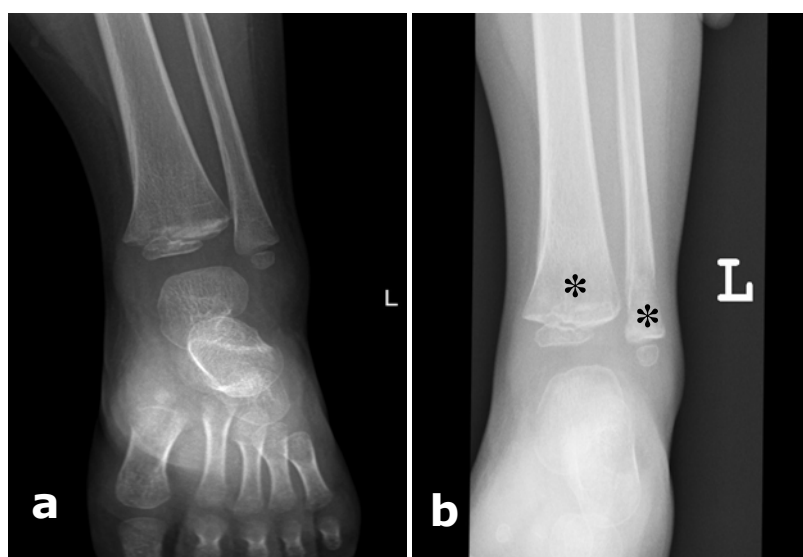
A 3-year-old boy had recurrent visits with a non-traumatic, painful swollen left ankle that was associated with fever. He initially presented with a week history of painful swollen left ankle. Examination revealed swollen, tender and erythematous left lateral malleolus. Radiograph of the ankle (Figure 1a) was reported as normal and the full blood count (FBC) was also unremarkable apart from a mild lymphocytosis. He was treated as cellulitis and discharged with oral cloxacilin and paracetamol.

He presented again a week later with persistent left ankle pain and refusal to weight bear. He was febrile (38°C) and other vital signs were normal. The swelling and erythematous area had improved. The ankle was still tender but had normal passive range of motions. He received further a course of treatment with cloxacilin and paracetamol.

al weeks later in the clinic for unresolved left ankle pain. This time he had developed some degree of weight loss. He was pale with no organomegaly or lymphadenopathy. He was admitted to the ward with presumed diagnosis of septic arthritis affecting the left ankle. A left ankle arthrotomy was performed and this showed non-septic synovial fluid. This was negative on Gram staining and culture.

A FBC and differential profile were done and this revealed mild anaemia, thrombocytopenia and a significantly elevated lymphocyte count. The blood profile revealed 57% of blast cells which was absent in the earlier investigations. The summaries of sequential haematological parameters are presented in Table 1. A radiograph of the left ankle was repeated and this showed radiolucent changes that were not seen in the initial radiograph (Figure 1b).

In view of the persistent haematological alterations and no clinical improvement, a bone marrow aspiration was performed. This showed the presence of more than 90%



**Figs. 1: a) Radiograph of the left ankle which was normal and, b) repeat radiograph of the left ankle showing metaphyseal radiolucent lesion (asterisks) and cortical erosion in distal fibula.**

**TABLE 1: Sequential haematological parameters of the patient.**

|                                 | 5/4/2013<br>(First presentation) | 14/4/2013 | 25/4/2013      | 2/5/2013<br>(Diagnosis of ALL) |
|---------------------------------|----------------------------------|-----------|----------------|--------------------------------|
| Hb (gm/dl)                      | 12.2                             | 10.6      | 8.9            | 7.5                            |
| Leucocytes (10 <sup>9</sup> /L) | 5.6                              | 5.2       | 4.3            | 4.4                            |
| Neutrophils (%)                 | 15.9                             | 19.9      | 21.5           | 22.3                           |
| Lymphocytes (%)                 | 72.6                             | 77.3      | 73.8           | 72.5                           |
| Platelet (10 <sup>9</sup> /L)   | 161                              | 75        | 89             | 66                             |
| LDH (U/L)                       |                                  |           | 681            | 712                            |
| CRP (mg/dl)                     |                                  |           | 0.80           | 3.07                           |
| Blood film                      |                                  |           | No blast cells | 57% of blast cells             |

Hb: haemoglobin; CRP: C-reactive protein; LDH: lactate dehydrogenase

blasts cells, compatible with a diagnosis of precursor-B ALL.

Induction chemotherapy was initiated with asparaginase, vincristine and intrathecal methotrexate which resulted in a complete remission. The joint pain rapidly resolved and the patient was discharged following three weeks of admission. He remained well without any recurrence of symptoms and was in remission on long-term follow up.

## DISCUSSION

Musculoskeletal manifestations may be the only presenting symptoms in childhood leukaemia and this account for between 10% and 62% of ALL cases.<sup>2</sup> The presenting symptoms are usually non-specific but bone and muscle pain are relatively common at the disease onset.<sup>1</sup> ALL may masquerade as many orthopaedic conditions such as septic arthritis, osteomyelitis or even cellulitis and this can often lead to misdiagnoses as in our case.<sup>4</sup> Duarte-Salazar *et al.* reported that the ankle joints are most frequently involved among the joints in childhood leukaemia.<sup>5</sup> A history of excruciating nocturnal pain, inability

to walk and joint pain that is out of proportion to physical findings are common.<sup>6,7</sup>

Routine investigations are generally non-specific and can be subtle or even normal, further adding on to the diagnostic dilemma. 'Near normal' haematological indexes have been reported in the literature.<sup>6-8</sup> A case-control reported that the presence of 'low-normal platelet' count (150-250 x 10<sup>9</sup>/L) and leucopaenia were the most sensitive and specific findings in children with leukemia presenting with musculoskeletal manifestations.<sup>6</sup> Gupta *et al.* reported that neutropoemia with predominant lymphocytosis were common subtle haematological changes seen in their young patient with leukaemia.<sup>7</sup> Our case had subtle abnormalities seen in the initial differential counts (lymphocytosis and neutropoemia) and subsequent blood counts revealed persistent thrombocytopenia and neutropoemia with predominance of lymphocytes consistent the experience of Gupta *et al.* However, in our case the actual diagnosis was only made when the haematological changes persisted and became more obvious. Improvement after the initial course of antibi-

otic probably contributed to the delay. Furthermore, both acute cellulitis or septic arthritis are also characterised by leucocytosis.

Blood profiles may show a few or absence of blast cells at the early stages of disease,<sup>6, 7</sup> similar to our case. A study found that blast cells were absent in the peripheral blood in up to 53% of children with ALL.<sup>6, 8</sup> Therefore, bone marrow study should be considered in patients with unexplained lymphocytosis, leucopaenia and thrombocytopenia even in the absence of blasts in the peripheral blood film. Elevated serum LDH which reflects increased cell proliferation should also alert the clinician the possibility of leukaemia instead of other diagnosis. A twofold or more increase in the serum LDH was found to be a useful parameter in diagnosing ALL in children.<sup>6</sup>

Radiographic osseous abnormalities, although may raise the suspicion of acute leukemia are not pathognomonic. The most frequent radiological abnormalities described as being suggestive of leukaemia are diffuse osteopaenia, radiolucent metaphyseal bands, osteolytic lesion and sclerotic lesions.<sup>1, 6</sup> However, these changes may not be evident at the onset of the disease. Only 6% of ALL cases were reported to have the mentioned lesions.<sup>1</sup>

In conclusion, our case illustrates the need to consider acute leukemia in any child with persistent musculoskeletal pain, subtle haematological and radiological alterations. The presence of persistent and unexplained lymphocytosis and neutropaenia should alert

physicians to the possibility of this disease, especially when there are additional typical radiological abnormalities such as osteopaenia, radiolucent metaphyseal bands, osteolytic lesion and sclerotic lesions.

**ACKNOWLEDGEMENT:** We thank Prof Dr Ismail Bin Saiboon, the Head of Department of Emergency, UKMMC and Prof Dr Srijit Das, Department of anatomy UKM for their invaluable comments, teaching and contribution.

#### REFERENCES

- 1:** Mulder H, Herregods N, Mondelaers V, et al. Musculoskeletal manifestations in children with acute lymphoblastic leukaemia. *Belg J Hematol.* 2012; 3:3-11.
- 2:** Serra-Bonett N, Guzman Y, Rodriguez E, et al. Acute leukaemia in children erroneously diagnosed as idiopathic juvenile arthritis. *Rheumatol Clinic.* 2008; 4:70-3
- 3:** Onubogu UC, Okoh BAN, Eke G, et al. Acute lymphoblastic leukaemia presenting as juvenile idiopathic arthritis in a Nigerian boy. *Niger J Paed* 2013; 40:431-3.
- 4:** Sakamoto S, Oiso N, Emoto M, et al. Cellulitis with leukocypenia as an initial sign of acute promyelocytic leukemia. *Case Rep Dermatol.* 2012; 4: 47-9.
- 5:** Duarte-Salazar C, Santillan-Chapa CG, Gonzalez-Rosado GD, et al. Arthritis: An unusual and anticipatory presentation of paediatric acute lymphoblastic leukaemia. *Cir Cir.*2012; 80:455-8.
- 6:** Jones OY, Spencer CH, Bowyer SL, et al. A multi-center case-control study on predictive factors distinguishing childhood leukaemia from juvenile rheumatoid arthritis. *Paediatric.* 2006; 117:840-4.
- 7:** Gupta D, Singh S, Suri D, et al. Arthritic presentation of acute leukaemia in children: Experience from a tertiary care centre in North India. *Rheumatol Int.* 2010; 30:767-70.
- 8:** Maman E, Steinberg DM, Stark B, et al. Acute lymphoblastic leukemia in children: Correlation of musculoskeletal manifestations and immunotypes. *J Child Orthop.* 2007; 1:63-8.