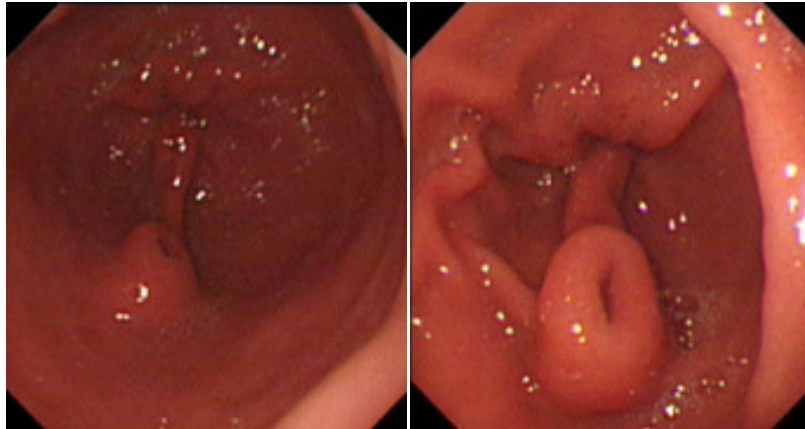


Vui Heng CHONG



A 34-year-old lady was referred for chronic dyspepsia. This was treated with antacids with some relief of symptom. Serum amylase and the liver profile were normal. An ultrasound scan of the abdomen did not show any gallstones or any abnormality with the pancreas. She underwent upper gastrointestinal endoscopy. This showed mild gastritis and rapid urease test was negative for *Helicobacter pylori*. However, there was an incidental finding of a polypoidal lesion with a punctum in the antrum (**Panels**).

Q: What is the diagnosis?

Answer: refer to page 301

Correspondence author: Vui Heng CHONG
Department of Medicine, RIPAS Hospital,
Bandar Seri Begawan BA 1710,
Brunei Darussalam.
Tel: +673 2242424 Ext 5233
E mail: chongvuih@yahoo.co.uk