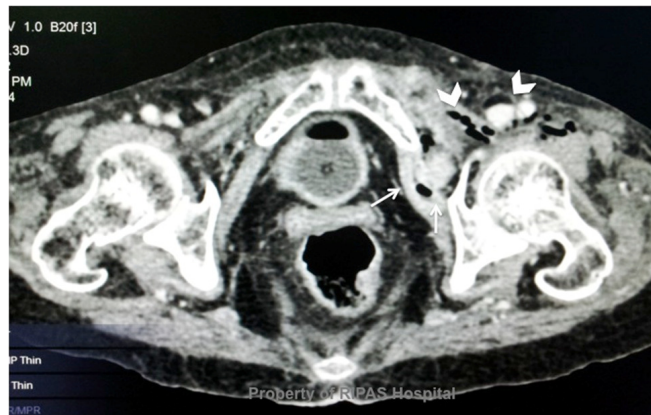


Chee Fui CHONG



A 65-year old lady presented with three days history of constipation, increasing left thigh and abdominal pain, accompanied by abdominal distension. On examination, the abdomen was slightly distended with tinkling bowel sounds. The left groin was particularly tender with a tender lump felt on palpation. A computed tomography scan of the abdomen was done which showed some small bowel distension in the left iliac region (**Panel**).

Q: What is the diagnosis?

Answer: refer to page 300

Correspondence author: Chee Fui CHONG
Department of Surgery, RIPAS Hospital,
Bandar Seri Begawan BA 1710,
Brunei Darussalam.
Tel: +673 2242424 Ext 6280
E mail: wcfchong@gmail.com