

**(Refer to page 206)**

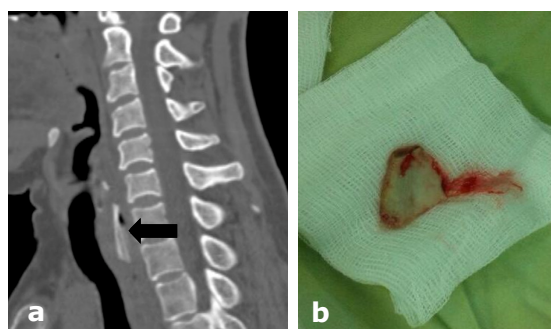
**Answer: Foreign body in the upper oesophagus**

A flat 3 x 2cm bone was removed from cervical oesophagus just below the cricopharyngeal sphincter about 17cm from the incisor teeth which was impacted posteriorly (**Panel**). The prevalence of ingested FBs varies geographically, depending on the eating habits of the locality. In the Asian population, because of cooking and consumption of fish, chicken and meat on the bone, ingested FBs are a major clinical problem. FB impaction occurs primarily in children, in edentulous or mentally impaired elderly subjects. Our patient had limited dentition and was consequently swallowing food rather than chewing and swallowing. Because the bone was impacted posteriorly she was able to eat and drink food.

Eighty percent of ingested FBs pass without the need for intervention. Symptoms in the throat can be categorised into supra-cricoid, cricoid or infra-cricoid. Supra-cricoid FBs can be identified, but also can be removed during examination.<sup>1</sup> Those patients with negative clinical examination can be safely discharged and followed up as our patients if necessary. Infra-cricoid FBs should be removed promptly as possible or else should be admitted and monitored. When FBs become impacted in the infra-cricoid or oesophagus, they often do so at the sites of

physiologic or pathologic luminal narrowings.<sup>2</sup> Physiologic narrowings are: the upper oesophageal sphincter, level of the aortic arch, and the diaphragmatic hiatus. The pathologic narrowings can be due to oesophageal webs, rings, tumours, strictures, diverticula and achalasia. These patients must undergo rigid or flexible oesophagoscopy for identification and removal of FB. Complications of FB or food impaction include ulcer formation, laceration, perforation, aorto-oesophageal fistula formation, trachea-oesophageal fistula formation and bacteraemia.<sup>3</sup>

FBs in the oesophagus should not be left in situ for more than 24 hours from presentation due to increased risk for complications. Emergency endoscopy is indicated in patients with sharp-pointed objects, batteries, and in patients with complete oesophageal obstruction. Failing removal by endoscopy, especially for larger FBs, patient should proceed to rigid oesophagoscopy under general anaesthetic.



A sagittal computed tomography image (a) showing the done fragment (arrow) and the extracted bone fragment (b).

**REFERENCES**

- 1: Lam CH, Woo JK, Van Hasselt CA. Management of ingested foreign bodies: a retrospective review of 5240 patients. *J Laryngol Otol.* 2001; 115:954-7.
- 2: Li ZS, Sun ZX, Zou DW. Endoscopic management of foreign bodies in the upper-GI tract: experience with 1088 cases in China. *Gastrointes Endosc* 2006; 64:485.
- 3: Eisen GM, Baron TH, Dominitz JA, et al for American Society for Gastrointestinal Endoscopy. Guidelines for the management of ingested foreign bodies. *Gastrointestine Endoscopy* 2002; 55:802-6.