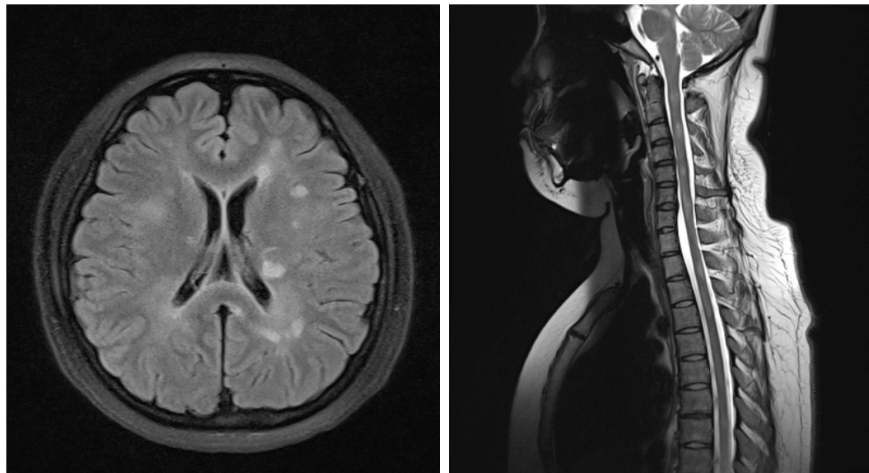


Christopher BONG and Ian BICKLE



A 23-year-old Chinese lady presented with a three week history of progressive bilateral lower limb weakness. On examination, the lower limb tone, power and sensation were normal with unequivocal Babinski reflexes. Horizontal nystagmus was present and Romberg's test was positive. The patient also developed paraesthesia in the entirety of her left leg two days after hospital admission. Magnetic Resonance Imaging (MRI) scans of the brain and spine (**Panels**) as well as a lumbar puncture were performed.

Q: What is the diagnosis?

Answer: refer to page 229

Correspondence author: Ian C BICKLE
Department of Radiology, RIPAS Hospital,
Bandar Seri Begawan BA 1710,
Brunei Darussalam.
Tel: +673 2242424 Ext 6503
E mail: firbeckkona@gmail.com