

Giant pancreatic mucinous cystadenoma with malignant transformation

Jerica CHAI ¹, Vui Heng CHONG ², Ian BICKLE ¹

¹ Department of Radiology and ² Department of Medicine, RIPAS Hospital, Brunei Darussalam

ABSTRACT

Pancreatic cystic lesions are uncommon and most are detected incidentally. They can be categorised into inflammatory and non-inflammatory or non-neoplastic and neoplastic. Inflammatory pancreatic cyst, pseudocysts occur in association with pancreatitis. Non-inflammatory cysts can be non-neoplastic or neoplastic. Cystic neoplasms include serous cystadenoma, mucinous cystic neoplasms, intraductal papillary mucinous neoplasms and solid pseudopapillary neoplasms. Cystic neoplasms, with the exception of the serous variant have malignant potential and need to be evaluated and followed up. Imaging represent an important part of the evaluation. Most lesions are small to moderate upon detection and large or giant lesions are rare. We report the case of a 43-year-old lady who presented with a giant mucinous cystic lesion and discuss on cystic lesions of the pancreas and the imaging features that may help to differentiate these lesions.

Keywords: Cystic neoplasm, mucinous cystadenoma, cystadenocarcinoma, pancreatic neoplasm

INTRODUCTION

Pancreatic cystic lesions are generally uncommon and can be categorised into either inflammatory and non-inflammatory or non-neoplastic and neoplastic. ¹ Inflammatory pancreatic cysts are pseudocysts that occur in association with pancreatitis. The non-inflammatory cysts can be non-neoplastic or neoplastic. Pancreatic cystic neoplasms especially the mucinous types have malignant potential and need to be evaluated and followed up. ¹ Differentiating these different cystic

lesions is still difficult without histological evaluations. Radiological investigations such as ultrasound and computed tomography scans represent an important part of the evaluation as they can provide important information that may provide clues to the underlying types of cysts. However, endoscopic ultrasound a favoured investigation as it allows cysts characterisation and tissue sampling with low complications rate. ¹ Most cystic lesions are detected incidentally and are small to moderate. Large or giant lesions are rare. ⁴ ⁻⁶ We report the case of a 43-year-old lady who presented with a giant mucinous cystic lesion and discuss on cystic lesions of the pancreas and the imaging features that may

Correspondence author: Ian BICKLE
Department of Radiology, RIPAS Hospital,
Bandar Seri Begawan BA 1710,
Brunei Darussalam.
Tel: +673 2242424 Ext 6306, Fax: +673 2242690
E mail: firbeckkona@yahoo.co.uk

help to differentiate these lesions.

CASE REPORT

A 43-year-old Malay lady was referred with increasing upper abdominal discomfort over the past three weeks. This was intermittent and was associated with feeling of fullness. She also reported five kilograms of weight loss over the past 12 months. Apart from this, she denied any other symptoms. Her past medical history was only relevant for hypertension. There was also no family history of any gastrointestinal cancers. She was a non-smoker and did not consume any alcohol.

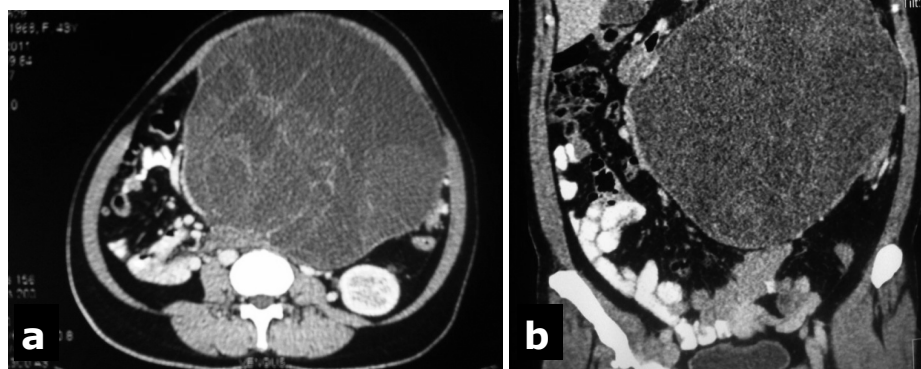
Physical examination revealed a firm mass in the left upper quadrant, extending beyond the umbilicus. Examinations of the other systems were unremarkable. Investigations demonstrated mild microcytic anaemia and slight derangement with her prothrombin time (13.7 sec, Normal <11) but INR was normal (1.2). Serum tumour markers were elevated; carcinoembryonic antigen (CEA) of 10.39 (<5) and the carbohydrate antigen (CA 19-9) of 2,637 U/ml (0-37). The rest of her investigations, including inflammatory markers (C reactive protein, CRP and erythrocyte sedimentation rate, ESR), thyroid function, liver function tests, amylases and lipases were all normal.

A computed tomography (CT) was performed and this showed a large cystic tumour with thin septations arising from the body and tail of the pancreas (Figures 1). The tumour measured 26cm x 24cm. Being so large (size >5cm), the tumour displaced organs adjacent to it. These findings suggested very strongly the possibility of a giant mucinous cystic pancreatic tumour.

The patient was advised to have a surgical resection. However, despite detailed discussions and persuasions, the patient and family declined any intervention and wanted to try traditional treatment. She was advised to return at any time should she change her mind or develop new symptoms. Unfortunately she failed to return for her scheduled appointment and did not return after being contacted by phone.

A review of her past medical history revealed that she had presented twice previously for similar complaints but had not disclosed this information. The first presentation was four years previously. She was seen by the surgical service, and an ultrasound and CT

Figs. 1: a) A contrast enhanced axial computed tomography image showing a giant septated cystic lesions of the pancreas with displacement of the adjacent organ, b) A sagittal image of the cystic lesion.



scans had demonstrated a 13-cm multi-septated cystic mass in the pancreatic body and tail, suggestive of a mucinous cystic tumour. A serum CA 19-9 level was mildly elevated at 36.46 U/ml (<37). At that time, she also had declined any intervention and had missed her follow-up appointment. Seven months following that presentation, she again presented to the Emergency Department with similar complaints, but declined admission or any further intervention. She failed to return for her outpatient follow-up appointments.

She represented several months after the last admission with deterioration of her condition with weight loss, increasing abdominal distension and general debilitation. Tumour markers was markedly elevated suggestive of malignant transformation. Imaging showed the cystic lesions and ascites. Aspiration of the cystic lesion and ascites showed malignant cells consistent with malignant cystic lesion of the pancreas. She was referred to the palliative care team for further management. She died several weeks later.

DISCUSSION

In the evaluation of pancreatic cystic lesions, it is important to differentiate the types of lesions as the treatment or follow up strategies are different. Currently, pancreatic cystic lesions are categorised as inflammatory and non-inflammatory or neoplastic or non-neoplastic. There is overlap between these two classifications. Inflammatory cysts are often associated with pancreatitis. Although benign, they can be associated with significant comorbidity and even mortality due to underlying pancreatic problems or sepsis. Non-inflammatory cystic lesions include cystic neoplasms, true benign pancreatic cysts or other

less common lesions. Cystic neoplasms broadly include other cystic lesions and it is important there are associated with malignancies. It is probably better to categorise cystic lesions into neoplastic or non-neoplastic. Table 1 summarises the type of pancreatic cystic lesions, characteristics and malignant potential.

Given that these lesions are now are diagnosed with increasing frequency and often detected incidentally on abdominal imaging done for other indications.⁴ This creates a major challenge for clinicians who have to manage these patients given the difficulty with making a reliable diagnosis. From the patients' point of view, it creates a lot of anxiety in addition to the added cost of investigations and being off work. Therefore, clinicians should be aware of the various types of cystic lesions of the pancreas, their management and the controversies that still surround them.

True cystic have cuboidal epithelial lining and are benign. These do not require any treatment unless there is superadded infection or increase in size to cause symptoms from mass effects. Lympho-epithelial cysts are lined by mature keratinising squamous epithelium that is surrounded by a layer of lymphoid tissue. The natural history of these benign cysts is not very clear at present. Generally infective seeding of cysts lesions, benign or neoplastic are uncommon and often occur after aspiration or biopsy. Pseudocysts in association with pancreatitis although benign requires follow up, especially the bigger ones. Retention cysts are a consequence of pancreatic duct obstruction causing dilated pancreatic side branches. Currently, the natural history of this lesion is also uncertain. Mucinous non-

neoplastic cysts are very similar to neoplastic mucinous cysts. Both have mucinous lining but on histology, mucinous non-neoplastic cysts do not have neoplastic features or any ductal communication

Among the types of cystic neoplasms, serous cystadenoma is the most common. It is lined by glycogen-rich cells from pancreatic centro-acinar cells. These are more commonly found in women over the age of 60. Malignant transformation in these tumours is very rare and usually a conservative approach is adopted.

MCNs occur more commonly in women and typically after the age of 40. Characteristically, they arise in the body or tail of the pancreas without any communication with the pancreatic duct. They usually demonstrate variable cellular atypia, ovarian-like stroma and secrete mucin. MCNs display greater risk of malignancy and the recommended approach is surgical resection in appropriate candidates. Recurrence after surgery has not yet been reported.^{1, 4}

IPMN occur in both male and female, typically over the age of 50. They are mucin-producing papillary neoplasm of the ductal neoplasm which causes dilatation of pancreatic ducts. Their main differentiating features include diffuse or segmental dilatation of the pancreatic duct without structuring, the intra-ductal expansion of mucin-producing ductal cells and dilatation of either or both pancreatic orifices. Management include surveillance and/ or resection. On endoscopy, the pancreatic orifice is often patulous and described as 'fish mouth' appearance with mucin seen coming out. On pancreatogram, the ducts will

be dilated with long linear filling defects from the mucin.

Solid pseudo-papillary neoplasms or Franz's tumour is probably the least common type of cystic neoplasms. It commonly occurs in young women (under the age of 35 years old). They usually arise in the body or the tail of the pancreas and may contain both solid and cystic components and occasional calcifications. The endoscopic ultrasound appearance is described as mainly solid lesion with multiple cystic spaces without septations is characteristic for this lesion. However, a biopsy will still be required to make a firm diagnosis.

The malignant potential of mucinous cystic neoplasm was estimated to be 11% in one study, 38% in another and 6-35% in the third study.^{6, 7} However, these are also dependent on the grade of dysplasia which ranges from low-grade dysplasia to invasive adenocarcinoma. Other features suggestive of a higher risk of malignancy include: thickened or irregular cyst wall, calcification in the cystic wall (or possible calcification), internal solid component or mass.⁵⁻⁷ These features can be visualised with imaging in particular CT scan and endoscopic ultrasound. Laboratory investigations are of little value unless the serum tumour markers, in particular CA 19-9 and CEA are elevated. Cyst fluid analyse have been reported to be useful in predicting malignancy.

The treatment of cystic neoplasms depends on whether there is suspicious malignant transformation, the malignant potential, size and symptoms. Large cystic lesions including benign lesions should be resected if

symptomatic. For those lesions proven to be malignant or are highly suspicious such as our patients should proceed to surgeries. Studies have repeatedly supported surgical resection as a treatment for choice, which improves patient's morbidity and mortality. For smaller cystic lesions categorised as cystic neoplasms can be followed with interval imaging. However, currently there is not recommendation for the interval.

As most lesions are detected incidentally, most are small and giant lesion such as our patient is very uncommon. To date, only a few cases have been reported in the literature. Interestingly, in our patient with a cyst measuring 26 by 24 cm in dimension did not experience many symptoms. Her complaints were intermittent abdominal discomfort and fullness. Our patient clearly requires surgery but unfortunately despite persuasion and explanation regarding the risk of malignancy, she had adamantly declined any intervention.

In conclusion, we report a rare case of a giant cystic neoplasm of the pancreas which on imaging was consistent with a mucinous cystadenoma with little in the way of troubling symptoms. To our knowledge, this is probably the largest cystic adenoma of the pancreas ever reported in the literature.

NOTE: Jerica CHAI is a fourth year medical student from the Medical School of University of Otago, New Zealand, who was attached to the Department of Radiology.

REFERENCES

1: Khalid A, McGrath K, Saltzman JR, Travis AC. Classification of pancreatic cysts. UpToDateOnline 2011. Accessed 28th June, 2011 ([http://www.uptodate.com/contents/classification-of-](http://www.uptodate.com/contents/classification-of-pancreatic-cysts)

[pancreatic-cysts](http://www.uptodate.com/contents/classification-of-pancreatic-cysts) source=search_result&selectedTitle=2%7E5)

2: Le Borgne J, de Calan L, Partensky C. Cystadenomas and cystadenocarcinomas of the pancreas: a multiinstitutional retrospective study of 398 cases. French Surgical Association. *Ann Surg.* 1999; 230:152-61.

3: Warsaw AL, Compton CC, Lewandrowski K, Cardenosa G, Mueller PR. Cystic tumors of the pancreas. New clinical, radiologic, and pathologic observations in 67 patients. *Ann Surg.* 1990; 212:432-43.

4: Khalid A, McGrath K, Saltzman JR, Travis AC. Pancreatic Cystic Neoplasm. UpToDateOnline. 2011. Accessed 28th June 2011, (http://www.uptodate.com/contents/pancreatic-cystic-neoplasms?source=see_link&anchor=H18#H18)

5: Gress F, Gottlieb K, Cummings O, Sherman S, Lehman G. Endoscopic ultrasound characteristics of mucinous cystic neoplasms of the pancreas. *Am J Gastroenterol.* 2000; 95:961-5.

6: Zamboni G, Scarpa A, Bogina G, et al. Mucinous cystic tumors of the pancreas: clinicopathological features, prognosis, and relationship to other mucinous cystic tumors. *Am J Surg Pathol.* 1999; 23:410-22.

7: Reddy RP, Smyrk TC, Zapiach M, et al. Pancreatic mucinous cystic neoplasm defined by ovarian stroma: demographics, clinical features, and prevalence of cancer. *Clin Gastroenterol Hepatol.* 2004; 2:1026-31.

8: Fernández-del Castillo C, Targarona J, Thayer SP. Incidental pancreatic cysts; Clinicopathological characteristics and comparison with symptomatic patients. *Arch Surg* 2003; 138:427-33.

9: Zamboni G, Klöppel G, Hruban RH. World Health Organization classification of tumours. pathology and genetics of tumours of the digestive system. Lyon: IARC PRESS; 2000. p. 234-6.

10: Tokuyama Y, Osada S, Sanada Y, Takahashi T, Yamaguchi K, Yoshida K. Mucinous cystic neoplasm of the pancreas in a male patient. *Rare Tumors* 2011; vol 3 edi 14.

11: Gan SI, Thompson CC, Lauwers GY, Bounds BC, Brugge WR. Ethanol lavage of pancreatic cystic lesions: initial pilot study. *Gastrointest Endosc.* 2005;

61:746-52.

12: Oh HC, Seo DW, Lee TY, et al. New treatment for cystic tumors of the pancreas: EUS-guided ethanol lavage with paclitaxel injection. *Gastrointest Endosc.* 2008; 67:636-42.

13: Fernández-del Castillo C. Mucinous Cystic Neoplasms. *Int J Gastrointest Surg.* 2008; 12:411-3.

14: Howell DA, Shah RJ, Lawrence C, Whitcomb DC (ed), Travis AC (ed). Diagnosis and management of pseudocysts of pancreas. In UpToDateOnline. 2011. Accessed 28th June 2011, (http://www.uptodate.com/contents/diagnosis-and-management-of-pseudocysts-of-the-pancreas?source=see_link)

15: Donahue TR, Hines OJ, Ashley SW (ed), Pories SE (ed). *Distal Pancreatectomy: Techniques.*

UpToDateOnline 2011. Accessed 28th June 2011 (http://www.uptodate.com/contents/distal-pancreatectomy-techniques?source=see_link)

16: Sheth SG, Howell DA, Kent TS, Whitcomb DC (ed), Travis AC (ed). Intraductal papillary mucinous neoplasm of the pancreas. UpToDateOnline. 2011. Accessed 28th June, 2011 (http://www.uptodate.com/contents/intraductal-papillary-mucinous-neoplasm-of-the-pancreas?source=see_link&anchor=H14#H14)

17: Gourgiotis S, Germanos S, Ridolfini MP. Liver, pancreas and biliary tract: Clinical review: presentation and management of pancreatic cystic neoplasms. *J Clin Gastroenterol.* 2007; 41:599-608.