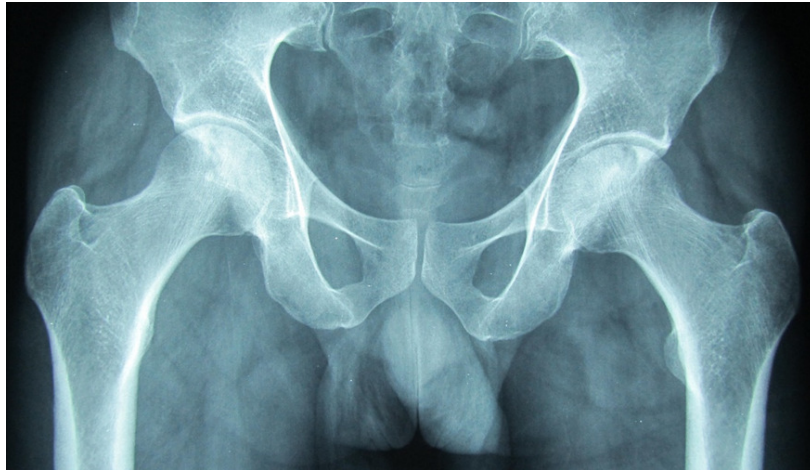


Mohammad Abdul Hafidz YAKOB and Ketan PANDE



A 30-year-old Indian man presented with difficulty in squatting and pain in both thighs that were referred to his knees. On examination he was noted to have restricted hip flexion and internal rotation. The knee joints were normal. The patient has asthma and had previously treated with oral steroids. He also admits to previous excess alcohol intake. A plain radiograph of the hips is shown (**Panel**).

Q: What is the diagnosis?

Answer: refer to page 185

Correspondence author: Ketan PANDE
Department of Orthopaedics, RIPAS Hospital,
Bandar Seri Begawan BA 1710,
Brunei Darussalam.
Tel: +673 2242424 Ext 5614
E mail: ketanpande@yahoo.com