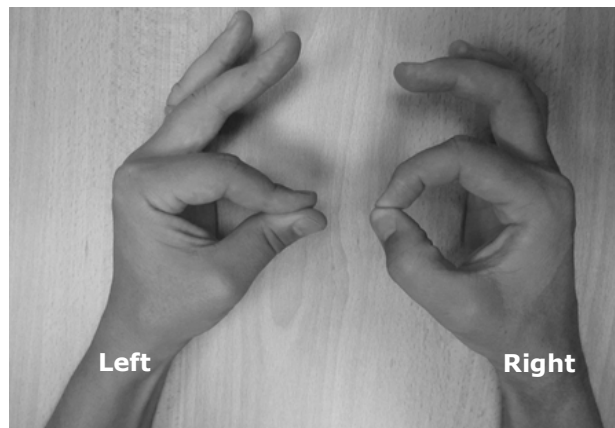


Sonali PANDE



A 50-year-old gentleman complained of difficulty in pinching and holding a key with his left hand. He had sustained injury to his left upper limb six months previously the onset of symptoms. (**Panel**).

Q: What is the diagnosis?

Answer: refer to page 119

Correspondence author: Sonali PANDE
Jerudong Park Medical Centre
Jerudong Park
Brunei Darussalam
Tel: +673 2611433
E mail: ladyorthopod@yahoo.co.in