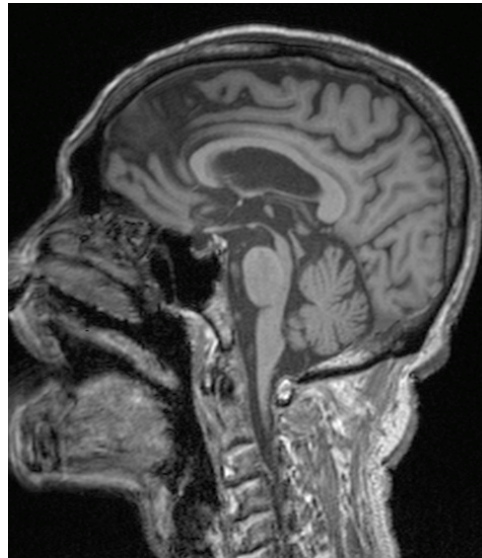


**Ian C BICKLE and Tahir NAEEM**



An elderly man was referred with history of difficulty with walking, tremors and postural symptoms. On examination, he had mask like features, tremors, rigidity, difficulty in gazing upward and also stooping small steps gait. He underwent a Magnetic resonance imaging (MRI) of the brain (**Panel**).

**What sign is shown in the MRI image?**

**Answer:** refer to page 59

**Correspondence author:** Ian C BICKLE,  
Department of Radiology,  
RIPAS Hospital, Bandar Seri Begawan BA 1710,  
Brunei Darussalam.  
Tel: +673 2242424 Ext 6306  
E mail: firbeckkona@gmail.com