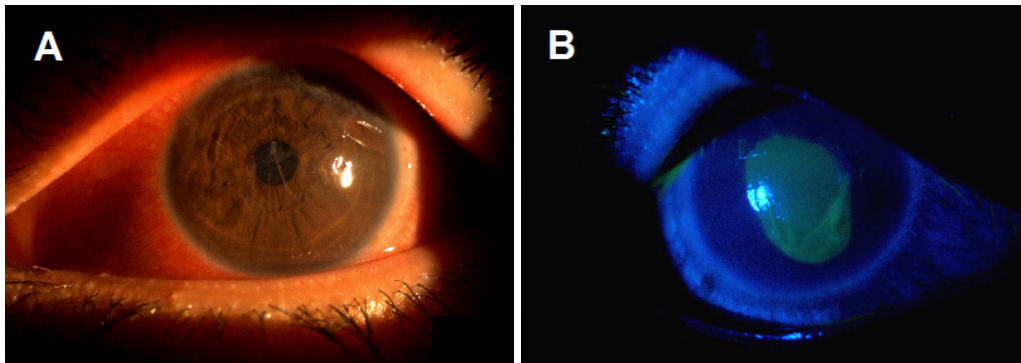


**Azimuddin Azim SIRAJ and Nayan JOSHI**

This 35-year-old male presented with symptoms of watering and photophobia in his left eye following a fight half an hour earlier. He declared that his eyes were normal before the fight. Upon evaluation, the vision in his left eye was 6/36, and his eye was mildly congested. On casual evaluation, his left eye's cornea looked apparently clear (**Panel A**). Otherwise, his ocular evaluations were within normal limits. His right eye vision was 6/6 and his ocular evaluation was within normal limits. Visualisation with blue light after instilling 'a drop' revealed an abnormality with the left cornea (**Panel B**).

**Q: What is the diagnosis?****Answer:** refer to page 357

**Correspondence author:** Azimuddin Azim Siraj,  
Department of Ophthalmology,  
Suri Seri Begawan Hospital, Kuala Belait,  
Brunei Darussalam, KA - 1931.  
Telephone: +673 3335335  
E mail: azim\_siraj@yahoo.com