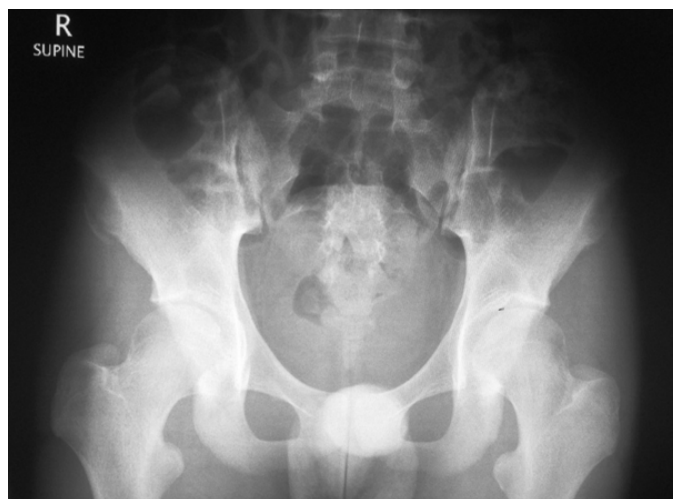


**Sonali PANDE and Ketan PANDE**



A 13-year-old boy presented with acute onset pain in the right groin when attempting to kick a football. The pain was severe and he had to come off the field. He was walking with a limp and had severe tenderness in the right groin. An radiograph was performed (**Panel**)

**Q: What is the diagnosis?**

**Answer:** refer to page 281

**Correspondence author:** Sonal PANDE  
Jerudong Park Medical Centre  
Jerudong Park,  
Brunei Darussalam  
Tel: +673 2611433  
E mail: ladyorthopod@yahoo.co.in