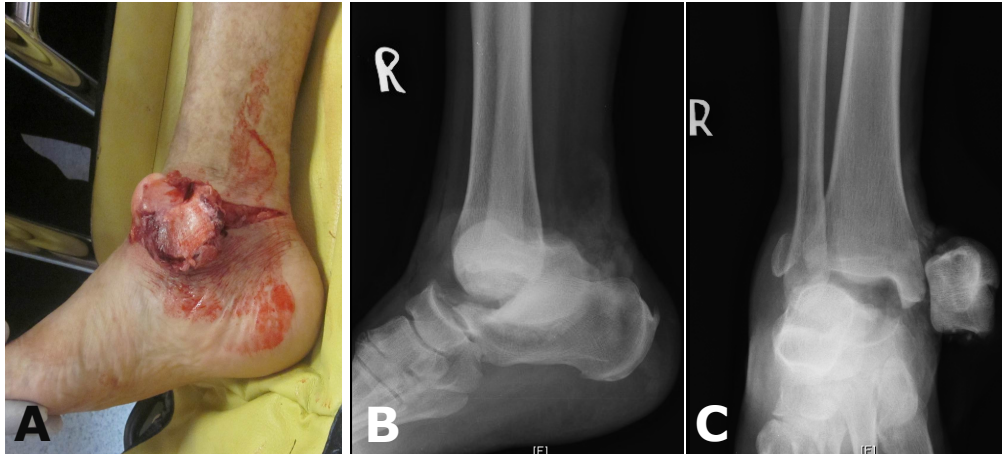


**Paisal HUSSIN, Kuhanrajan RAMALINGAM, Maliza MAWARDI,
Mahendran SUBRAMANIAM**



A 35-year-old Chinese man was brought to the Emergency Department after being involved in a road traffic accident. He was riding a superbike. On examination there was a wound over the ankle (Panel A) and the radiographs (Panel B, lateral and Panel C, anterior-posterior) are shown above.

What is the diagnosis?

Answer: refer to page 373

Correspondence author: Paisal HUSSIN
Department of Orthopaedic, Faculty of Medicine
and Health Sciences, Universiti Putra Malaysia,
43400, Serdang, Selangor, Malaysia.
E mail: paisalh@gmail.com