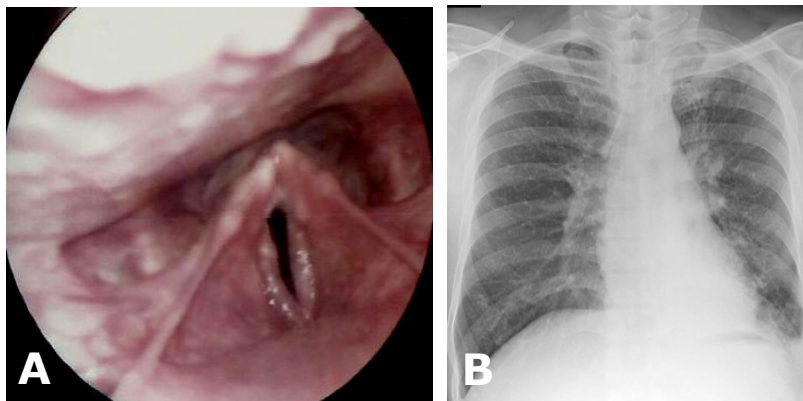


Irfan MOHAMAD, Nik Fariza Husna NIK HASSAN, Hazama MOHAMAD



A 43-year-old Malay man, a smoker of 25 years presented with hoarseness for the previous 11 months and a productive cough for the previous six months. This was associated with heart burn especially at night and frequent throat clearing. He denied any tuberculosis contacts, night sweats and other constitutional symptoms of tuberculosis. Laryngoscopic examination showed that the vocal cords were mobile but oedematous with irregular vibrating edge resulting in a phonation gap (**Panel A**). There was no frank ulcer or mass and the epiglottis, arytenoid and interarytenoid were normal. Erythrocyte sedimentation rate was 20mm/hr. A chest radiograph was performed (**Panel B**).

What is the diagnosis?

Answer: refer to page 282

Correspondence author: Irfan MOHAMAD
Department of Otorhinolaryngology-Head & Neck
Surgery, School of Medical Sciences,
Universiti Sains Malaysia Health Campus,
16150 Kota Bharu, Kelantan, Malaysia.
Tel: 609-7676420
E mail: irfan@kb.usm.my