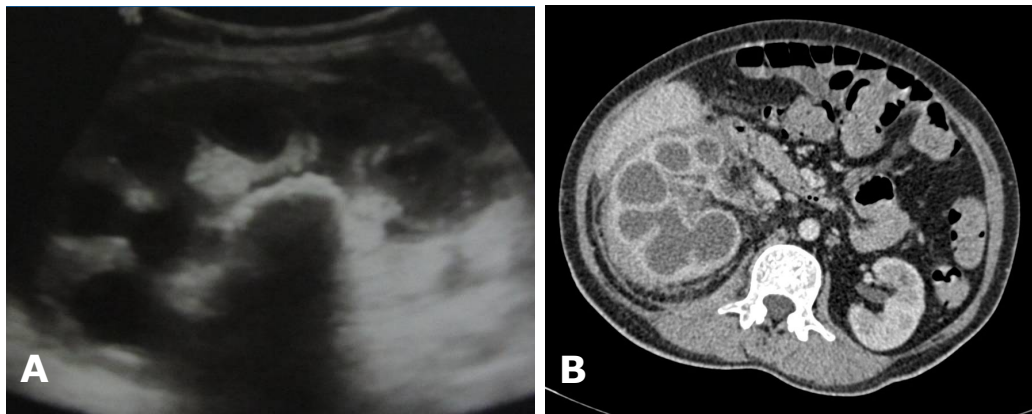


**Ian BICKLE**



A 47-year-old lady presented with a two-week history of right flank pain. She was afebrile, but had a raised white cell count. She had a past medical history of renal calculi. Following admission blood tests she was diagnosed as having diabetes mellitus. An ultrasound imaging detected some abnormalities (**Panel A**) and a computed tomography (CT) scan was done. The CT (**Panel B**) image is shown above.

**What is the diagnosis?**

**Answer:** refer to page 211

**Correspondence author:** Ian BICKLE  
Department of Radiology,  
RIPAS Hospital, Bandar Seri Begawan BA 1710,  
Brunei Darussalam.  
Tel: +673 2242424 Ext 6304  
E mail: clonvara@yahoo.co.uk