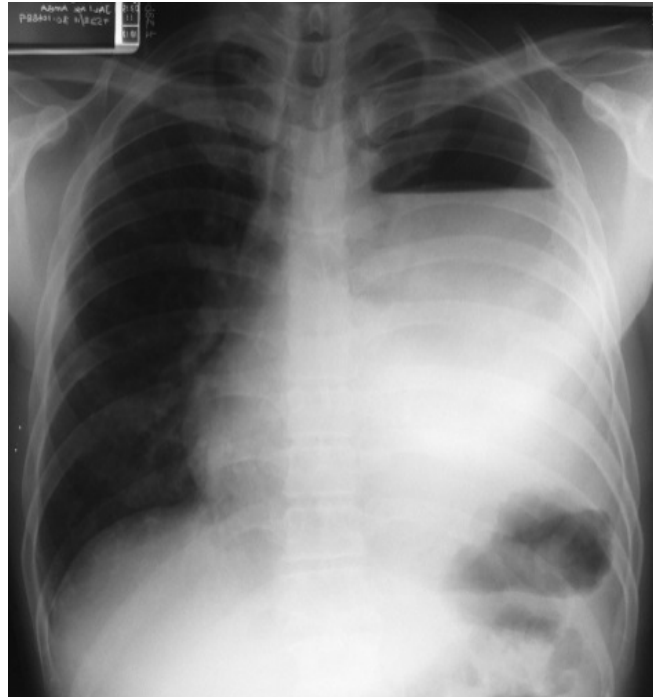


Eddy NGATEMO and Ian BICKLE



This 41-year-old man presented with a two week history of cough that was productive of green sputum. This was accompanied with fever and increasing breathlessness. The symptoms commenced soon after returning from the jungle. The presenting chest radiograph is shown (**Panel**). A diagnostic ultrasound and guided pleural drain insertion was performed.

What is the diagnosis?

Answer: refer to page 56

Correspondence author: Eddy NGATEMO,
Department of Accident and Emergency,
RIPAS Hospital, Bandar Seri Begawan BA 1710,
Brunei Darussalam.
Tel: +673 2242424 Ext 6629
E mail: medullaz@gmail.com