

# Snake venom ophthalmia

Sajid Adhi RAJA, Kenneth Yuh Yen KOK

Department of Ophthalmology, PMMPMHAMB Hospital, Tutong, Brunei Darussalam

## ABSTRACT

Snake venom ophthalmia is an acute reaction of the ocular surface tissues to venom ejected into the eyes of spitting cobra victims. The condition is uncommon and the victim may be frightful of going blind. However permanent vision loss is rare. This case (40-year-old man) is reported to discuss the management protocol in such cases. Immediate copious irrigation of the eye is the most important management measure. Topical antibiotics may be prescribed to prevent secondary keratitis. Local or systemic anti-venom, topical heparin or corticosteroids are contraindicated in the management of this uncommon form of envenoming.

**Keywords:** Cobra venom, management, ophthalmia

## INTRODUCTION

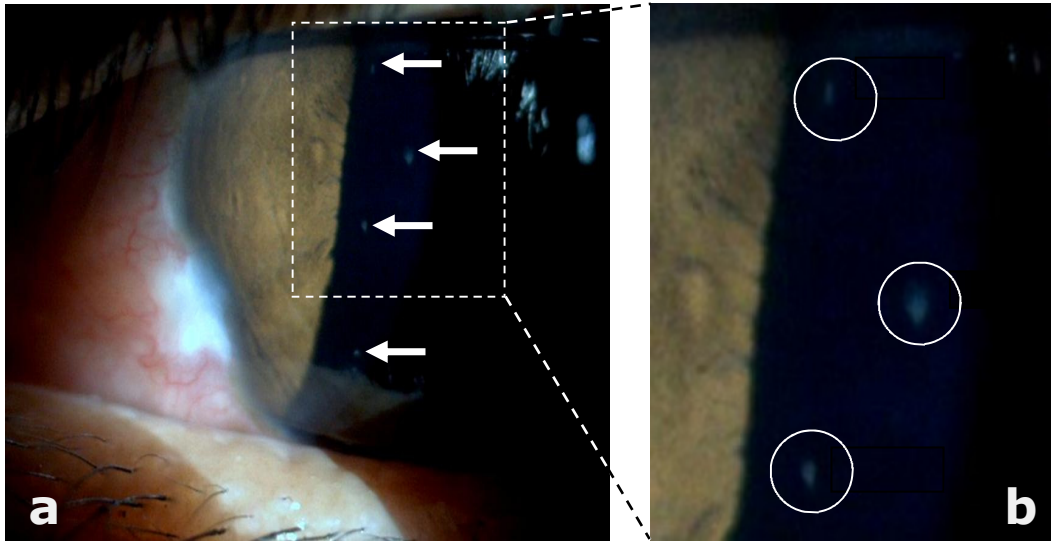
The cobra snake is one of the most venomous snakes in the world. All the cobra snakes belong to the genus *Naja* and have the characteristic hood which helps in their easy identification. There are more than 20 species of cobra; like the King cobra, which is found in Burma, China, India, Malaysia, Philippines, South Africa and Thailand; the Spitting cobra, which is found in Africa and parts of South East Asia; the Indian cobra, which is found in India and Central Asia; and the tree cobra, which is found in Central and Western equatorial Africa.

It is well known that bites by cobras can be lethal due to the neurotoxic nature of the snake venom. Spitting cobras can eject venom precisely into the eyes of their preys or predators. The effects of such envenoming, termed snake venom ophthalmia have been reported in the literature.<sup>1</sup> A recent review article cites 10 cases who received venom spats in their eyes causing snake venom ophthalmia.<sup>2</sup> We report herein of a man who received spitting cobra venom in his eyes and discuss the management of this uncommon condition.

## CASE REPORT

A 40-year-old man residing in a forest area in the Tutong district tried to catch with his bare hands, a snake that had crept into his house.

**Correspondence author:** KYK KOK  
PMMPMHAMB Hospital, Tutong,  
Brunei Darussalam.  
Tel: +673 8671072 or +673 2232024  
E mail: koky@brunet.bn



**Fig. 1: a) Slit lamp examination showing vertical superficial epithelial nebulous patches on the cornea (arrows) highlighted by box, b) magnified image of the highlighted section.**

He described the snake as three feet in length, grey to black in colour with white spots. The snake became aggressive, reared up and displayed its hood. The apprehended snake then "spat" venom directly into the man's eyes. He experienced very severe stinging pain and diminution of vision, associated with excess watering in his eyes and inability to keep the eyes open. He immediately washed his eyes under running tap water. A couple of hours later he was seen by the ophthalmologist at the district hospital.

He was noted to have blepharospasm and bilateral periorbital oedema. Visual acuity in both eyes was 6/9. Slit lamp examination revealed moderate conjunctival chemosis, few discrete vertical corneal epithelial nebulous patches that stained with fluorescein dye (Figure 1). Diffuse punctuate staining in other areas of cornea without nebulae were also seen. There was no anterior chamber reaction. Intraocular pressure was 14 mmHg in each eye. As his symptom of blepharospasm

was mild, only oral analgesia was prescribed. On follow up visit the following day, the lid oedema and epithelial lesions had already settled. Visual acuity improved to 6/6. Slit lamp examination was normal. A Google image search results for spitting cobras was shown to him; and he identified the snake as *Naja siamensis*.

## DISCUSSION

Spitting cobras belong to the elapid family of snakes. *Naja nigricollis* and *Hemachatus haemachatus* are species that are commonly found in Africa. *Naja siamensis* or the Indo-Chinese cobra is a species of spitting cobra that is found in the South-east Asian region.<sup>3</sup> It is one of the six spitting cobras found in Asia. It occupies a range of habitats including lowlands, hills, plains and woodland. It is sometimes attracted to human settlements because of the abundant populations of rodents in and around these areas. It is known to spit its venom up to a distance of three metre directly into the eyes of its attacker. Snake

venom ophthalmia due to *Naja atra* has been reported from China and Hong Kong. <sup>4</sup>The physiological mechanism of "venom spitting" has been studied and is described to be a precise reflex mechanism aimed at ejecting venom forcefully into the eyes of the victims. <sup>5</sup>The composition of spitting cobra venom has also been studied and found to contain a mixture of neurotoxins, cytotoxins, phospholipases and cardiotoxins. <sup>6</sup> Cardiotoxins have membrane lytic properties and is thought to be responsible for corneal erosions and conjunctival chemosis. <sup>7</sup>

The ocular effects of envenoming by spitting cobras has been reported in the ophthalmology literature. Fear of death or of becoming blind can cause extreme anxiety in the afflicted person. Various remedies including topical dilute anti-venom, <sup>4,6</sup> topical heparin <sup>6</sup> and topical tetracycline <sup>6</sup> have been claimed to be successful in the treatment of this uncommon condition. The above reported case highlights the fact that simple copious irrigation of the eyes with water alone may be all that is required to treat this condition. In case of corneal erosions prophylactic broad spectrum topical antibiotics may be needed to prevent keratitis. <sup>2</sup>

A recent review article on snake venom ophthalmia by Chu *et al.* described the clinical features seen in 10 cases. <sup>2</sup> Contact with snake venom results in an intensely painful diminution of vision associated with blepharospasm, periorbital oedema, conjunctival inflammation and chemosis. Initially there may be vertical spicular epithelial nebulae <sup>8</sup> which take up stain, as seen in our case. The epithelial cells lyse to form large epithelial erosions. The venom enzymes do not pene-

trate the corneal stroma which is made up of collagen and is unlikely to cause permanent corneal stromal opacification *per se*. The ocular effects of the venom depend on the proximity at which ejection of venom occurs and also on the duration of contact of ocular surface with venom. Systemic sequelae of snake venom ophthalmia have not been reported. <sup>2</sup> Habitually biting cobras like the Indian cobra (*Naja naja*) can sometimes eject venom under captivity. Provoked ejection of venom by a *Naja naja* which was held in captivity has been reported to cause a transient lower motor neuron type facial palsy which resolved in a few hours. <sup>2</sup> On the other hand, spitting cobras can also bite. <sup>9</sup>

Since the venom contains enzymes, longer duration of contact can be assumed to cause more severe damage. First aid by immediate washing in running water is very important in removing the venom from the eyes and help in preventing corneal complications. <sup>2</sup> Applying bland liquids such as milk in the eyes may also help. Topical vasoconstrictors or patching of the eyes may aid to reduce pain. <sup>2</sup> Topical broad spectrum antibiotics may be applied to prevent secondary keratitis. A case of complete recovery after topical application of anti-venom has been reported. <sup>4</sup> However, the WHO guidelines published in 2010 advised against the use of topical or intravenous anti-venom and topical corticosteroids. <sup>10</sup> The use of dilute anti-venom has no logical basis; and it may cause local irritation, adding to the patient's discomfort. Corneal collagenase activity is enhanced by topical steroids and in the presence of epithelial defects may cause corneal melting. Topical tetracycline and heparin have been used to treat snake venom ophthalmia. The basic cardio-

toxin in snake venom readily binds to the acidic sites in the tetracycline molecule and heparin, and both render the cardiotoxin inactive in experimental models.<sup>6</sup>

In conclusion, snake venom ophthalmia is an uncommon form of envenoming due to venom ejected by spitting cobras. It manifests as intensely painful blurry vision associated with transient superficial corneal nebulae, corneal epithelial erosions and conjunctivitis with chemosis. There is no evidence of systemic involvement following ocular envenoming in the literature. Elimination of venom rapidly by washing with water is a very effective first aid treatment. The condition usually resolves without any sequelae within 24 to 72 hours. Topical vasoconstrictors or patching of the eyes may be required to reduce pain. In case of corneal erosions prophylactic broad spectrum topical antibiotics may be needed to prevent infections. Topical or systemic antivenom is not indicated nor justified due to risk of anaphylaxis. Topical corticosteroids are also contraindicated.

## REFERENCES

- 1: Ridley H. Snake venom ophthalmia. *Br J Ophthalmol.* 1944; 28:568-72.
- 2: Chu ER, Weinstein SA, White J, Warrell DA. Venom ophthalmia caused by venoms of spitting elapid and other snakes: Report of ten cases with review of epidemiology, clinical features, pathophysiology and management. *Toxicon.* 2010; 56:259-72.
- 3: O'shea M, Halliday T. *Smithsonian Handbook: Reptiles and amphibians.* 1st ed. New York: Dorling Kindersley, Inc; 2002.
- 4: Fung HT, Lam KK, Wong OF, Lam TS. Local antivenom treatment for ophthalmic injuries caused by a *Naja atra*. *J Med Toxicol.* 2010; 6:147-9.
- 5: Young BA, Boetig M, Westhoff G. Functional bases of the spatial dispersal of venom during cobra "spitting". *Physiol Biochem Zool.* 2009; 82:80-9.
- 6: Cham G, Pan JC, Lim F, Earnest A, Gopalakrishnakone P. Effects of topical heparin, antivenom, tetracycline and dexamethasone treatment in corneal injury resulting from the venom of the black spitting cobra (*Naja sumatrana*) in a rabbit model. *Clin Toxicol.* 2006; 44:287-92.
- 7: Kao PH, Wu MJ, Chang LS. Membrane-bound conformation of *Naja nigricollis* toxin gamma affects its membrane-damaging activity. *Toxicon.* 2009; 53:342-8.
- 8: Pugh RN, Theakston RD, Reid HA. Malumfashi Endemic Diseases Research Project XIII. Epidemiology of human encounters with the spitting cobra, *Naja nigricollis*, in the Malumfashi area of northern Nigeria. *Ann Trop Med Parasitol.* 1980; 74:523-30.
- 9: Tan HH. Epidemiology of snakebites from a general hospital in Singapore: A 5-year retrospective review (2004-2008). *Ann Acad Med Singapore.* 2010; 39:640-7.
- 10: Warrell DA. In: Guidelines for the management of snake-bites: management of cobra spit ophthalmia. WHO Library Cataloguing-in-Publication data; 2010:123-4.