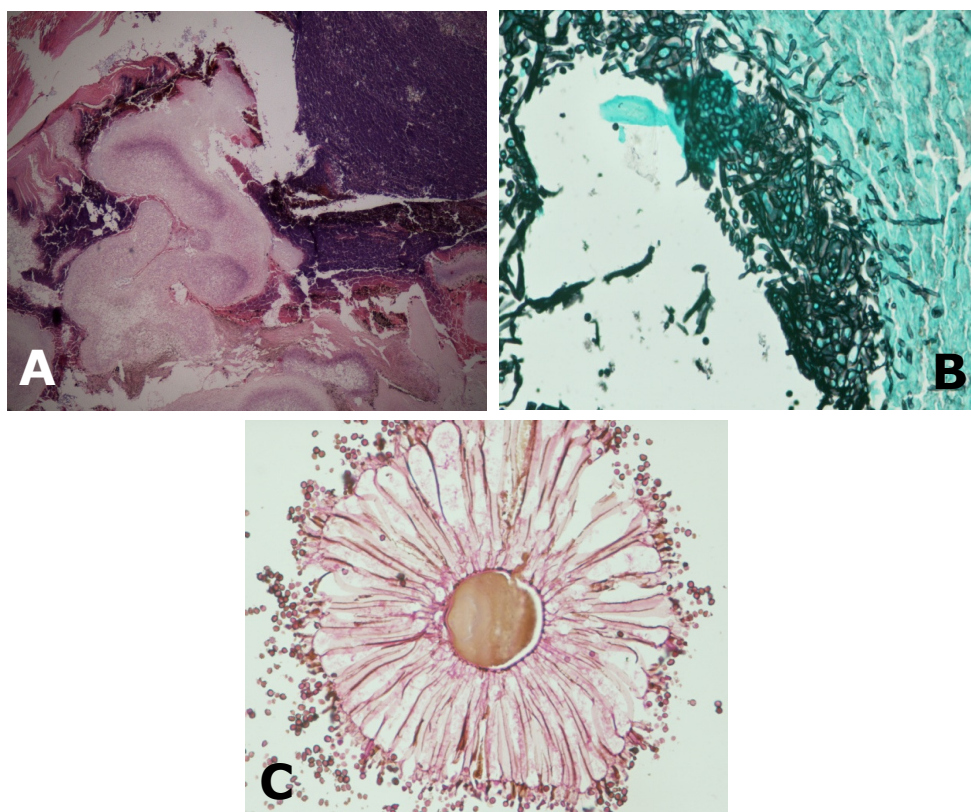


**Prathibha Parampalli SUBRAHAMANYA and Pemasiri Upali TELISINGHE**



A 59-year-old Malay man presented with a keratinising lesion over the dorsum of right toe. The resected specimen was an ulcerated necrotic skin covered lesion that measured 5 x 2.5 x 2.5 cm. The cut surface showed blackish powdery granular material embedded in nonviable tissue (**Panel A**; Haematoxylin and Eosin stain, **B**; Grocott (Silver) stain and **C**; Periodic Acid Schiff [PAS] stain).

**What is the diagnosis?**

**Answer:** refer to page 238

**Correspondence author:** PP SUBRAHAMANYA  
Department of Pathology,  
RIPAS Hospital, Bandar Seri Begawan BA 1710  
Negara Brunei Darussalam  
Tel: +673 2242424 Ext 6516  
E mail: prathibhaga@yahoo.com