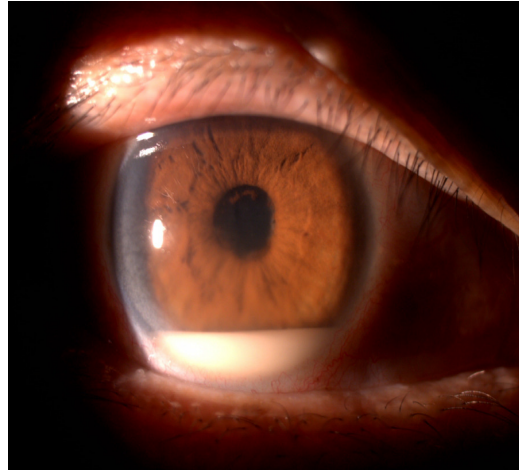


**Nadir Ali MOHAMED ALI, Ruben MATHEW, Nayan JOSHI**



A 55-year-old man presented with a five-day history of blurring of vision, pain and redness in the right eye. He had no significant past ocular or medical history, and gave no history of trauma. Ophthalmologic examination is shown above (**Panel**).

**What is the diagnosis?**

**Answer:** refer to page 235

**Correspondence author:** NA MOHAMED ALI  
Department of Ophthalmology  
RIPAS Hospital, Bandar Seri Begawan BA 1710,  
Brunei Darussalam.  
Tel: +673 8223690  
E mail: nadiramali@hotmail.com