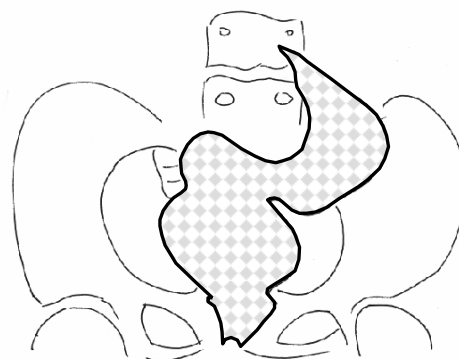


**(Refer to page 166)****Answer: Sigmoid Volvulus.**

There are three types of gastrointestinal tract volvuli: gastric, caecal and sigmoid. Sigmoid volvulus is the most common form and is responsible for eight percent of all intestinal obstructions. <sup>1</sup> Sigmoid volvulus is particularly common in the elderly and also psychiatric patients. Patients typically present with abdominal pain, distension, and absolute constipation. Predisposing factors to sigmoid volvulus include chronic constipation, a megacolon, and an excessively mobile colon.

Plain radiograph is almost always sufficient for the diagnosis of sigmoid volvulus and computed tomography (CT) should be reserved for special circumstances, such as concern regarding the presence of secondary ischaemic bowel. The plain radiograph appearances are usually pathognomonic with a large distended, relatively featureless loop of sigmoid colon arising out of the pelvis into the upper abdomen. The appearances give rise to the term '**coffee bean**' sign. A consequential large bowel obstruction results, and in the case of an incompetent ileo-caecal valve, the small bowel may also be dilated. Traditionally single contrast water soluble enemas have been performed, giving an abrupt cut off at the site of the volvulus, termed the '**bird of prey**' sign, due to its sharp beak like appearance. This is now very rarely performed. CT appearances are largely as per the plain radiograph; however the

'whirling' of the mesenteric vessels is classically apparent due to the twist in the sigmoid mesentery. <sup>2</sup>



'Bird of prey' sign on barium enema

Caecal volvulus is less common, tending to occur in younger females, who present with small bowel obstruction. The caecum twists, usually trans-locating in position to the upper abdomen giving rise to the '**empty caecum**' sign. The large bowel will be collapsed, but high grade small bowel obstruction is typical (*Refer to supplementary text for details of gastric, caecal and sigmoid volvuli*).

Treatment of sigmoid volvulus is usually with the insertion of a flatus tube, being successful in the majority of cases. <sup>3</sup> A post insertion plain radiograph will help confirm decompression of the volvulus. On occasion surgery is indicated, especially if volvulus is recurrent or if there is failure with tube decompression. This usually involves resection of the sigmoid colon with either a stoma formation or a primary anastomosis.

**REFERENCES**

- 1:** Atamanalp SS, Yildirgan MI, Basoglu M, et al. Clinical presentation and diagnosis of sigmoid volvulus: outcomes of 40-year and 859-patient experience. *J Gastroenterol Hepatol.* May 24 2007.
- 2:** Levsky JM, Den EL, DuBrow RA, Wolf EL, Rozenblit AM. CT Findings of Sigmoid Volvulus. *AJR* 2010; 194:136-143.
- 3:** Tan KK, Chong CS, Sim R. Management of acute sigmoid volvulus: an institution's experience over 9 years. *W J Surg.* 2010; 34:1943-8.