

Septal turbinates: An entity with physiological importance

Mawaddah AZMAN, Balwant Singh GENDEH

Department of Otorhinolaryngology-Head and Neck Surgery, Faculty of Medicine, Universiti Kebangsaan Malaysia, Malaysia

ABSTRACT

Septal turbinate refers to a widened region of the septum located superior to the inferior turbinates and anterior to the middle turbinates. Although a common anatomical variant, its significance is not well reported. We report a 56-year-old Malay man who presented with a three year history of chronic nasal obstruction secondary to septal turbinate and type II deviated nasal septum. His nasal symptoms improved dramatically following commencement of intranasal steroids. He remained free of symptoms during seven years of follow up. The physiologic implication and management of septal turbinates is discussed.

Keywords: Nasal obstruction, nasal septum, nasal mucosa, turbinates

INTRODUCTION

The term septal turbinate refers to a widened region of the septum located superior to the inferior turbinates and anterior to the middle turbinates. Although a common anatomical variant, it is not routinely noticed and is frequently overlooked by surgeons and radiologist. Its location in or near the distal segment of the nasal valve has potential to affect nasal airflow. We report a 56-year-old Malay man who presented with a three year history of chronic nasal obstruction secondary to septal turbinate and type II deviated nasal septum.

CASE REPORT

A 56-year-old Malay man presented with a three year history of intermittent nasal obstruction that was associated with post-nasal drip. There was no history of rhinorrhoea, sneezing or nasal itchiness. He denied any symptoms of sinusitis such as headaches or facial pain. Triggering factors included exposure to aeroallergens such as dust and cats' fur as well as cold weather. His background history was significant for ischaemic heart disease, hypertension and late onset bronchial asthma. His medications included aspirin, simvastatin, amlodipine and inhaled budesonide.

Cold spatula test revealed reduced but equal airflow bilaterally. Endoscopic examination revealed pale and hypertrophied

Correspondence author: Mawaddah AZMAN
Department of Otorhinolaryngology-Head and Neck Surgery, Faculty of Medicine,
Universiti Kebangsaan Malaysia, MALAYSIA.
Tel: +60391455555 Fax: +60391456675
E mail: mawaddah1504@yahoo.com

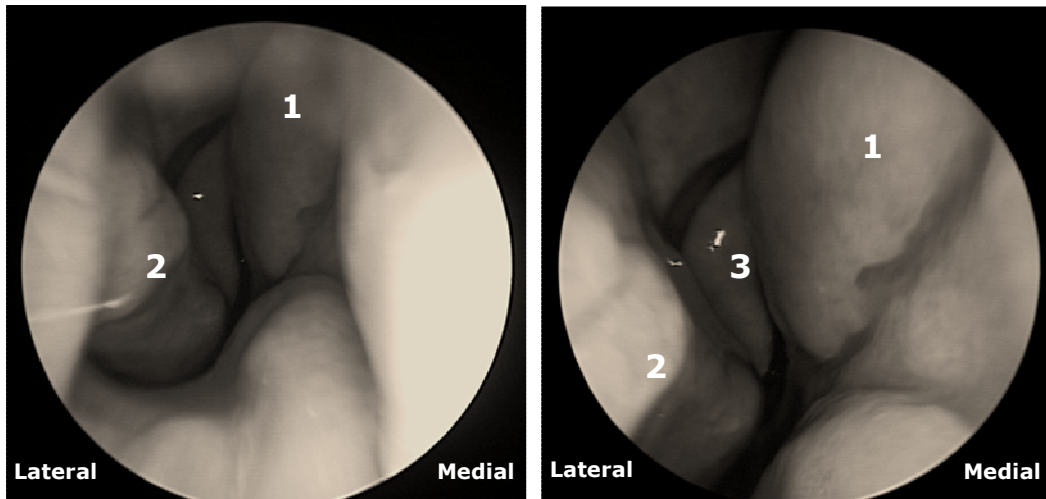


Fig. 1: Endoscopic views showing the patient's right nasal cavity; 1: Huge septal turbinate; 2: Inferior Turbinate; 3: Middle Turbinate; L: lateral wall of the nasal cavity; M: medial wall of the nasal cavity. Note the fusiform shape of the septal turbinate, located just superior to the anterior end of the inferior turbinate (2) and anterior to the middle turbinate (3).

inferior turbinates bilaterally. There was presence of septal turbinate on the right side of the septum with type II deviated nasal septum (*refer to supplementary text for classification*) to the left side touching the inferior turbinate (Figure 2). The osteomeatal complex area, frontal and sphenoidal recesses were normal. Other ear and throat examinations were normal.

Following commencement of intranasal mometasone fluorate 200 micrograms daily, he achieved dramatic symptomatic improvement (70-80%) in nasal obstruction. We have followed him up for seven years now whereby he was maintained on intranasal steroids and Montelukast Sodium. He continued to have good symptom control throughout his follow up.

DISCUSSION

The septal turbinate also referred to as nasal swell body (Schwellkörper am Septum Nasi), septal cavernous body, septal intumescence, anterior septal tuberculum, septal erectile

body and Kiesselbach's ridge was first described by Wustrow in 1951.¹ Although a common endoscopic finding, it is frequently under-documented and hence its importance under-appreciated. This is reflected by scarcity of publications pertaining to the septal turbinate, compared to the inferior turbinate. A radiological study found that 55.8% of patients with symptoms of chronic sinusitis have septal turbinates.⁴

Anatomically, the septal turbinate refers to a widened region of the septum located superior to the inferior turbinate and anterior to the middle turbinate, often part of the distal part of the nasal valve (Figure 3). This anatomical location is consistent and is easily identified during endoscopic or radiologic study.⁹ Given its location, it can have a significant impact in airflow regulation in the nasal cavity.

The nasal valve represents a major airflow resistive segment of the respiratory airways. It is confined to a short, narrow

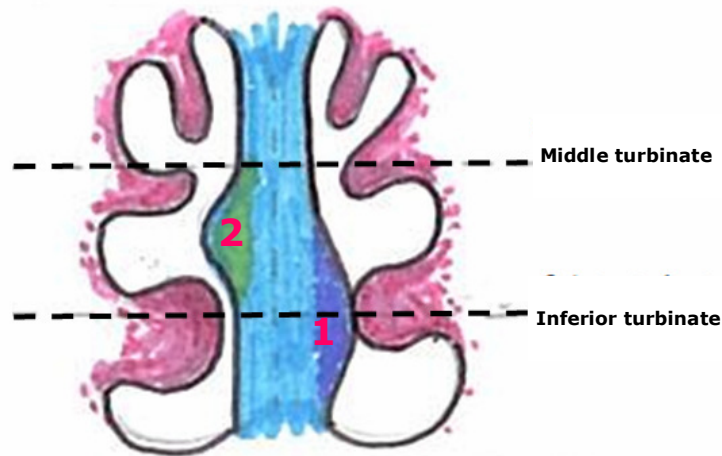


Fig. 2: Schematic representation of Type II septal deviation (1) at the level of the left inferior turbinate with septal turbinate (2) on the right side.

region bridging the pyriform aperture and extends from the caudal edge of the upper lateral cartilage in the vestibule to the anterior end of the bony inferior turbinate in the cavum. The angle between the septum and the upper lateral cartilage is 10-15°. The nasal valve is usually located less than 2cm distal in the nasal passage, approximately 1.3cm from the naris and the average cross-sectional area is 0.73 cm². The total nasal airway resistance from its three components (nasal vestibule, nasal valve and nasal cavum) constitute more than 50% of total airway resistance.

The septal turbinate, being a structural component of the nasal valve may cause a reduction in cross sectional area of the nasal valve and hence increase in the nasal airway resistance. The average mucosal thickness of the septal turbinate is 3.5mm with maximal thickness of 5mm in cadaver and it is suggested that its contribution to airway resistance must be significant given that this area of maximal septal thickness lies in the nasal valve.⁶ Even minute changes can result in symptomatic nasal obstruction. However, the vasoactive changes are less prominent compared to those caused by the inferior

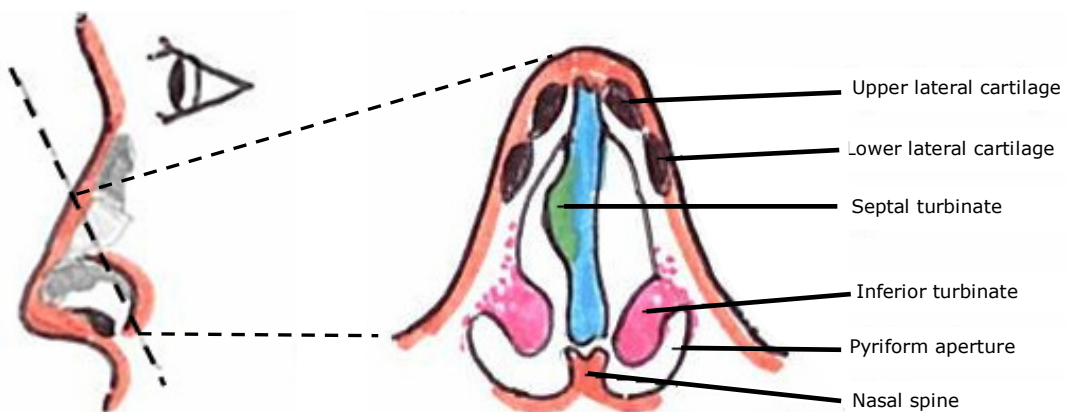


Fig. 3: Schematic representation of the septal turbinate and the internal nasal valve area.

turbinate.^{3, 5} The role of septal turbinate in allergy, immunologic, olfaction and temperature regulation is intriguing but is presently unclear.⁹

The underlying histologic features of septal turbinate are also not well studied. In separate studies, septal turbinate tissue has been shown to be non-sinusoidal,⁶ exhibits cavernous sinusoids that are less prominent compared to the inferior turbinate,⁷ and contains both glandular and vascular tissue elements. Septal turbinate has also been shown to contain prominent seromucinous glandular tissue in higher densities compared to the inferior turbinate. The abundance of glandular tissue suggests that these tissues may be well adapted for withstanding the drying effects of high airstream impact. Such high impact is expected as the septal turbinate redirects the airstreams towards the turbinate. Thus any consideration of septal turbinate reduction should aim at mucosal preservation as failure to do so can cause possible crusting, breakdown and epistaxis.⁷

Pharmacologic treatment remains the first line management of nasal obstruction even in the presence of septal turbinate and septal deviation. Intranasal steroid (mometasone fluorate 200 micrograms/day) has been shown to significantly ameliorate nasal resistance in patients with persistent non-allergic rhinitis.¹⁰ Anti-leukotrienes have also been shown to be efficacious in both allergic and non-allergic rhinitis nasal obstruction.¹¹

Surgery can be considered if pharmacologic therapies fail. Aggressive mucosal destructive procedures analogous to turbinate

trimming are considered inappropriate for the septal turbinate.^{6, 7} Removal of the seromucinous glands can result in excessive dryness and tissue dessication.

It is unknown whether the septal turbinate should be addressed regularly in the surgical management of patients with nasal obstruction. Haight and Gardiner showed there were no benefit in addressing septal turbinates when managing the inferior turbinate with cryotherapy and electrocautery. However, the result is not unexpected since cryotherapy and electrocautery causes destruction of the septal turbinate mucosa, hence less preferable.

In conclusion, septal turbinate is a normal structure. Though distinct anatomically and histologically is still poorly understood with regards to its clinical significance. Hence, further research it is required to determine the role of septal turbinate in possible treatment of nasal obstruction. This case highlights the role of pharmacotherapy in managing a patient with nasal obstruction in the presence of septal turbinate and septal deviation.

REFERENCES

- 1: Wexler DB, Davidson TM. The nasal valve: a review of the anatomy, imaging and physiology. *Am J Rhinol* 2004; 18:143-50.
- 2: Wustrow F. Septal turbinate. *Zeitschrift Anatomic Entwicklungsgeschichte* 1951; 116: 139-42.
- 3: Ng BA, Ramsey RG, Corey JP. The distribution of nasal erectile mucosa as visualized by magnetic resonance imaging. *Ear Nose Throat J* 1999; 78: 159-66.
- 4: Arslan M, Muderris T, Muderris S. Radiological Study of the intumescencia septi nasi anterior. *JLO* 2004; 18:3:199-201.
- 5: Cole P, Haight JSJ, Cooper PW. A computed

tomography study of the nasal mucosa: effects of vasoactive substances. *J Otolaryngol* 1983; 12:58-60.

6: Saunders MW, Jones NS, Kabala J. An anatomical, histological and magnetic resonance imaging study of the nasal septum. *Clin Otolaryngol* 1995; 20:434-8.

7: Wexler D, Braverman I, Amar M. Histology of the nasal septal swell body. *J Otolaryngol* 2006; 134:506-600.

8: Gupta A, Brooks D, Stager S, et al. Surgical access to the internal valve. *Arch Facial Plast Surg* 2003; 5:155-8.

9: Costa DJ, Sanford T, Janney C, Cooper M, Sindwani R. Radiographic and Anatomic characterization of the nasal septal swell body. *Arch Otolaryngol Head Neck Surg* 2010; 136:1107-10.

10: Sail GA, Zuo KJ, Xu G. Clinical effects of nasal glucocorticoid on amelioration of nasal obstruction in patients with persistent non-allergic rhinitis. *Zhonghua Er Bi Yan Hou Tou Jing Wai Ke Za Zhi.* 2009; 44:739-45.

11: Scadding GK, Durham SR, Mirakian R, et al. BSACI guidelines for the management of allergic and non allergic rhinitis. *Clin Exp Allergy.* 2008; 38:19-42.



World No Tobacco Day 2011

For more information <http://www.who.int/tobacco/wntd/2011/announcement/en/index.html>