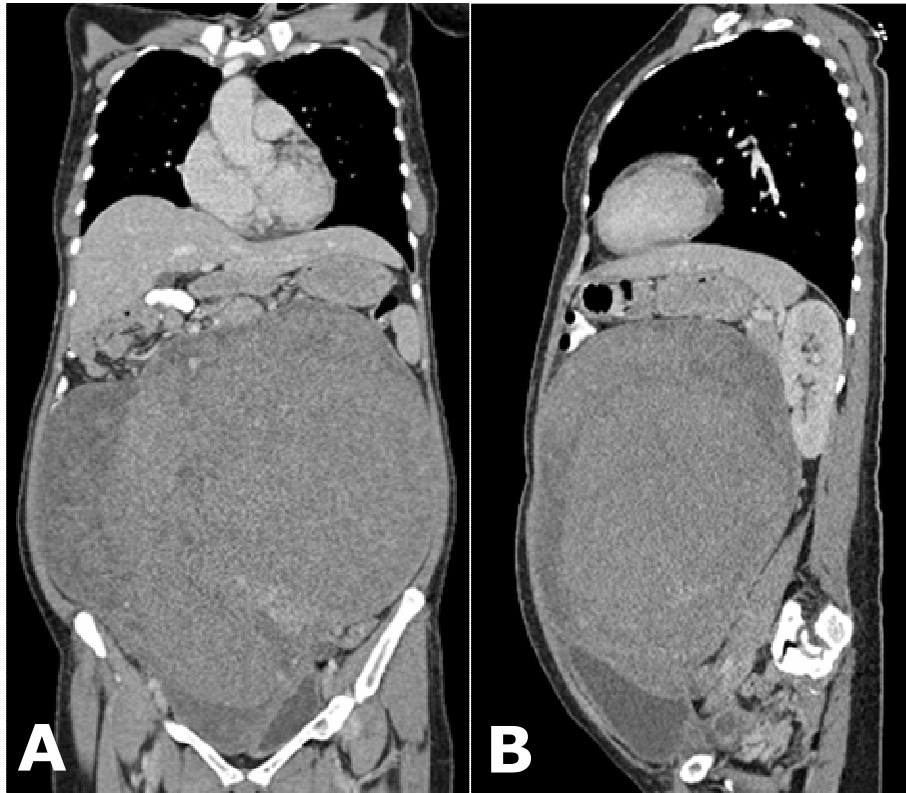


Ian BICKLE



A middle aged female presented to the Department of Obstetrics and Gynaecology complaining of lower abdomen swelling, which had been present for over a year, but getting progressively bigger over time. Ultrasound imaging confirmed the presence of a pelvic mass and imaging on multi-slice computed tomography (MSCT) are shown above: Coronal (**Panel A**) and Sagittal (**Panel B**) planes. Surgery was performed.

What is the diagnosis?

Answer: refer to page 58

Correspondence author: Ian C BICKLE
The Department of Radiology
RIPAS Hospital, Bandar Seri Begawan BA 1710,
Brunei Darussalam.
Tel: +673 2242424 Ext 6304
E mail: ian@bickle.co.uk