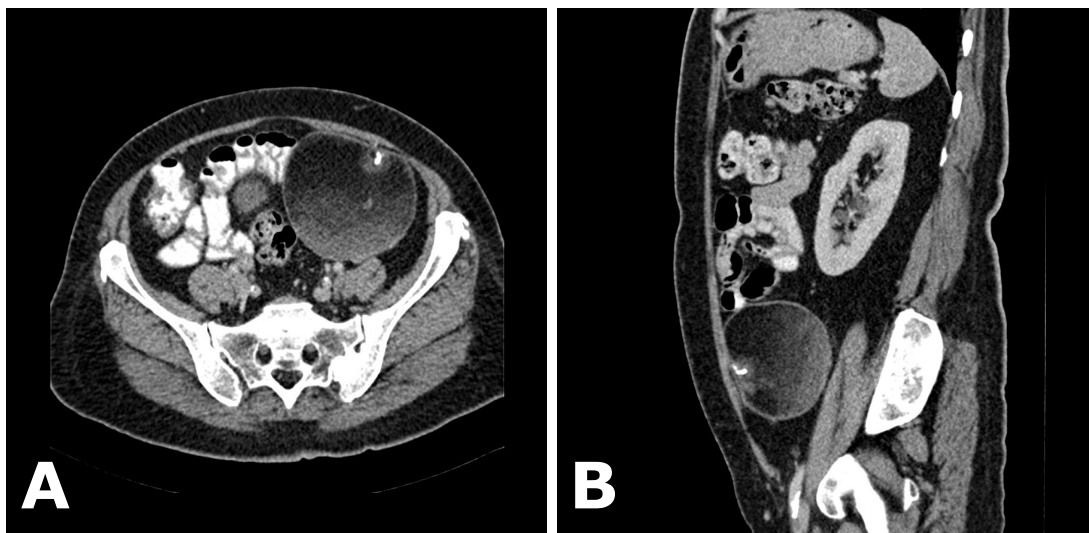


Ian BICKLE



A 52-year-old lady presented to clinic complaining of pelvic pain. She underwent ultrasound examination which identified a 9cm echogenic mass within the lower abdomen/pelvis, the exact origin of which was uncertain. Computed tomography (CT) scan of the abdomen and pelvis was recommended, selected images of which are shown in **Panel A** (Axial CT image) and **B** (Sagittal CT image).

Q: What is the diagnosis?

Answer: refer to page 57

Correspondence author: Ian C BICKLE
The Department of Radiology
RIPAS Hospital, Bandar Seri Begawan BA 1710,
Brunei Darussalam.
Tel: +673 2242424 Ext 6304
E mail: ian@bickle.co.uk