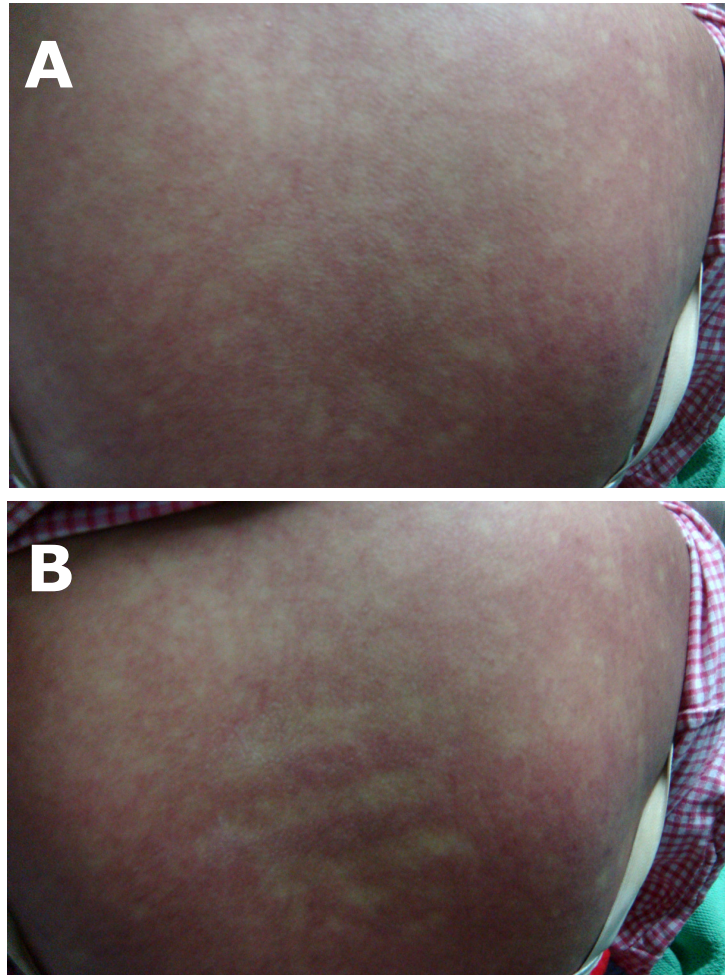


Hartini MISLI and Vui Heng CHONG



A 15-year-old girl was admitted to the hospital with a four day history of fever (between 38 to 39°C) and sore throat. There was also recent history of flooding in her town area. On examination, she had bleeding gums, blanching maculopapular rash all over her trunk and petechiae on her arms and legs. Her full blood count on admission showed pancytopenia. **Panel A** shows a typical rash over her back and **Panel B** was taken after placing fingers over the rash for a few seconds.

What is the diagnosis?

Answer: refer to page 56

Correspondence author: Hartini MISLI,
Department of Medicine, RIPAS Hospital,
Bandar Seri Begawan BA 1710,
Brunei Darussalam.
Tel: +673 2242424 Ext 7552
E mail: hartini131@gmail.com