

(Refer to page 49)

Answer: Gastric antral vascular ectasia or Watermelon stomach

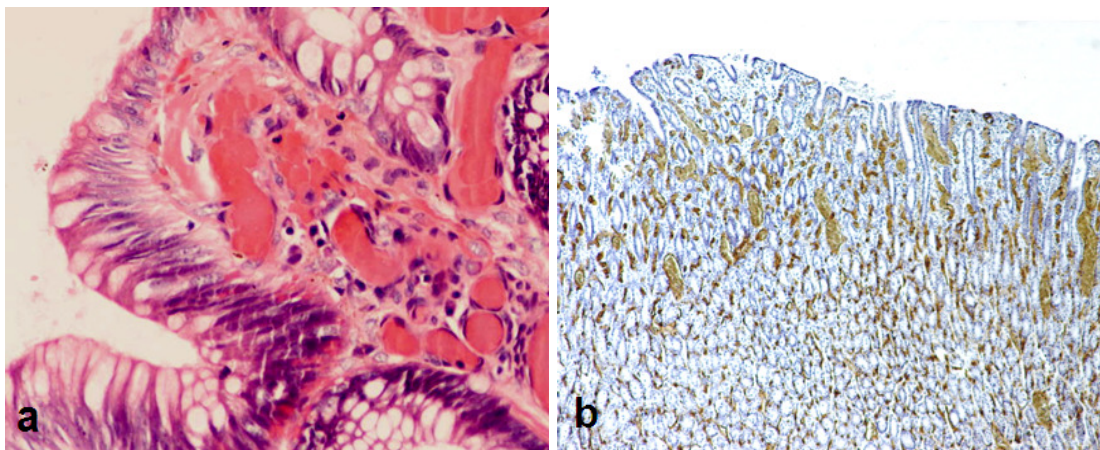
The endoscopy showed several antral inflammatory folds with linear red stripes running at the crests of the folds or parallel to the folds. These erythematous stripes are vascular ectasia, dilated vascular channels located within the mucosa and submucosa. Histology typically show fibromuscular hyperplasia of the lamina propria and dilated vascular channels with clots (**Panel a**). Special staining for vascular endothelium will show increase density (**Panel b**).

The endoscopic and histological findings of our patient are typical and characteristics for gastric antral vascular ectasia (GAVE), also known as the 'Watermelon stomach' due to the resemblance of the erythematous stripes to the peel of a watermelon.¹ Unless recognised, GAVE can be

easily misdiagnosed as severe antral gastritis depending on the severity of the condition.² Apart from stripes pattern, manifestations can also be diffuse affecting a large area of the antrum. Other part of the stomach can also be affected and the other most commonly affected site is near the cardia and at the gastro-oesophageal junction area.

GAVE is commonly associated with autoimmune connective disorders and liver cirrhosis. However, in our experience, GAVE is more commonly associated with end stage renal failure. The exact underlying pathogenesis is unknown.

GAVE commonly manifest as chronic iron deficiency anaemia requiring regular transfusions. The treatment of choice is with local ablations of the vascular ectasia using either argon plasma coagulations or laser.³



REFERENCES

- 1: Jabbari M, Cherry R, Lough JO, Daly DS, Kinneer DG, Goresky CA. Gastric antral vascular ectasia: the watermelon stomach. *Gastroenterology.* 1984; 87:1165-70.
- 2: Yüksel O, Köklü S, Başar O, Yüksel I, Akgül H. Erosive gastritis mimicking watermelon stomach. *Am J Gastroenterol.* 2009; 104:1606-7.
- 3: Sebastian S, O'Morain CA, Buckley MJ. Review article: current therapeutic options for gastric antral vascular ectasia. *Aliment Pharmacol Ther.* 2003; 18:157-65.