

# Primary angiosarcoma of the breast

Sonal TRIPATHI, Oo PAW, Varkey Vallikad MATHEW

Department of Surgery, RIPAS Hospital, Brunei Darussalam

## ABSTRACT

Breast cancer is increasing and is the most common cancer among females in Brunei Darussalam. Most are ductal carcinoma. We report a case of a 40-year-old woman who was diagnosed with primary angiosarcoma of the right breast, a rare condition. To the best of our knowledge this is the only reported case in Brunei Darussalam. She underwent lumpectomy followed by mastectomy as the resection margins were not clear. No adjuvant therapy was given because the size of tumour was small, there was no residual tumour in mastectomy specimen and she had no distant metastasis.

**Keywords:** Angiosarcoma, breast neoplasm, breast self examination, tumour

## INTRODUCTION

Angiosarcoma of the breast is an uncommon tumour. Two hundred and nineteen cases have been reported since the first case was reported by Schmidt in 1887.<sup>1</sup> The frequency of this rare tumour is 0.04% of primary breast tumours.<sup>2</sup> Less than ten percent of all angiosarcomas originate from the breast.<sup>2</sup> The incidence of angiosarcoma is estimated at between 0.002% to 0.005% per year.<sup>3</sup> In the literature, only isolated cases of primary angiosarcoma of the breast are described. Secondary angiosarcoma is more frequently diagnosed in patients who underwent breast conserving surgery and who underwent postoperative radiotherapy.<sup>4,5</sup>

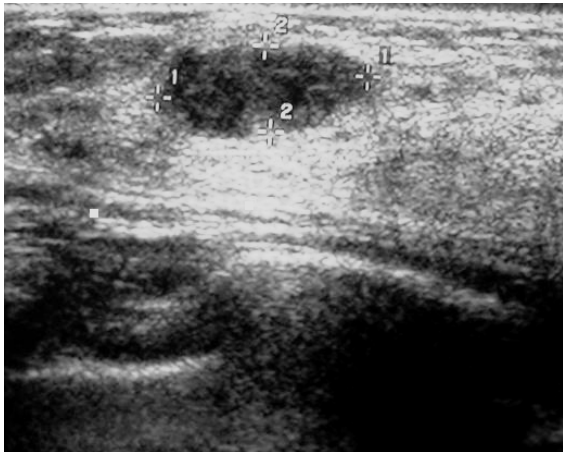
## CASE REPORT

A 40-year-old lady presented to RIPAS Hospital in January 2006 with a lump in the right breast, which she noticed on self breast examination three weeks before presentation. She was married with two children and there was no family history of any breast disorder. She had been on progesterone depot for the last three years for contraception. She had no other significant past medical problem.

On examination she had a well-defined firm, mobile lump (2 x 2 cm) located on outer upper quadrant of right breast, with no palpable axillary nodes. The left breast was normal. The rest of the examination was normal.

A mammogram showed a small opacity in right upper outer quadrant with fine spiculated margins. No micro-calcification was seen. Ultrasound scan showed a well-defined

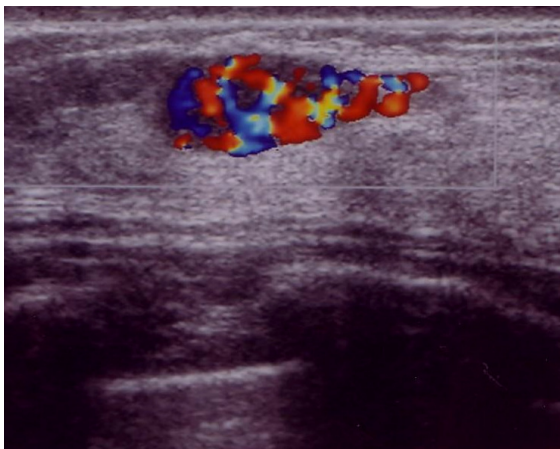
**Correspondence author:** Sonal TRIPATHI  
Department of Surgery,  
RIPAS Hospital, Bandar Seri Begawan BA 1710,  
Brunei Darussalam.  
Tel: +673 8660850 or +673 2450449  
E mail: sonal230167@yahoo.com



**Fig 1: Ultrasound scan showing a well-defined lesion.**

hypoechoic nodule (Fig. 1), extending to axillary tail. The lesion showed significant vascularity on colour flow (Fig. 2), suggesting a possibility of malignant tumour.

A fine needle biopsy was performed and only yielded blood stained fluid. Due to vascular nature of the lesion, a core biopsy was not advised. She underwent a lumpectomy with frozen section on 14<sup>th</sup> January 2006. Frozen section was reported as consistent with angiosarcoma of the right breast (1 x 0.6 cm); a further wide local excision of tumour with a level one axillary clearance was performed.



**Fig 2: Ultrasound doppler scan showing increased vascular signals consistent with a malignant tumour.**

Her post operative recovery was satisfactory. The paraffin section report confirmed angiosarcoma of intermediate grade (Fig. 3 and 4) (tumour cells stained positive with CD 34, CD 31 and Factor VIII related antigen). Unfortunately, the tumour was close to one of the resected margins. All eight lymph nodes only showed reactive changes.

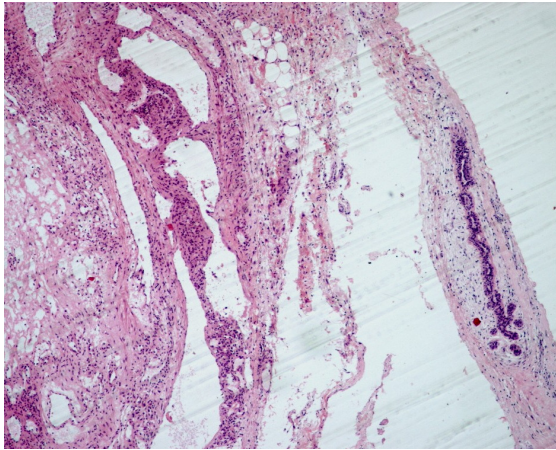
As a result, she underwent right mastectomy one week after the first operation. Histological examination of the mastectomy specimen showed no residual tumour. Bone and CT scan of the thorax and abdomen confirmed the absence of any metastasis. With the above histology report it was decided not to treat her with any adjuvant therapy.

Regular six monthly follow up did not show any signs of recurrence. Repeat CT scan of abdomen and thorax after two year was normal with no metastasis. Mammogram of left breast was also normal.

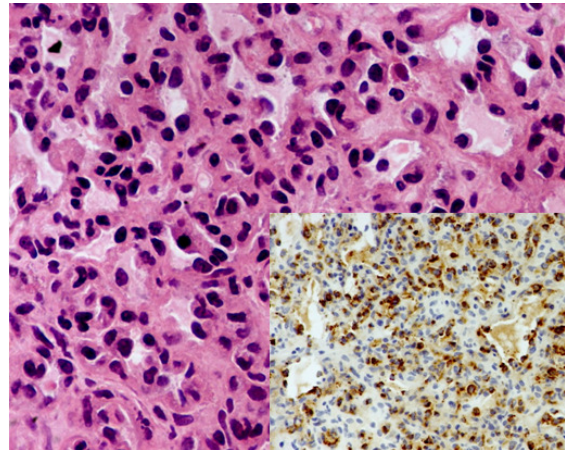
## DISCUSSION

Primary angiosarcoma of the breast is a rare tumour that is typically seen in pre menopausal women, in contrast to breast carcinoma which is more common in post menopausal women.<sup>4</sup> In Brunei Darussalam, breast cancer is the most common cancer among females with 79 cases diagnosed in 2009 and the incidence is increasing.

Clinically angiosarcoma of the breast may present as a painless mass or general enlargement of breast without definitive mass.<sup>3</sup> A case has been reported where a patient presented with a bleeding lesion that was later diagnosed to be angiosarcoma of the breast. Our patient was fortunate that she



**Fig 3: Vascular spaces of variable size with breast parenchyma on the edge (H&E stain, x10).**



**Fig 4: Vascular spaces lined by plump endothelial cells showing hyperchromatic nuclei with nucleoli and mitoses (H&E stain, x40). The cells were F-8 positive (insert).**

had noticed the lump on breast self examination and sought medical attention.

Delay in diagnosis is a common problem with angiosarcoma.<sup>5</sup> Radiographic features of breast angiosarcoma are non-specific. Similarly, ultrasound scan is also non-specific. In our case, the ultrasound colour flow scan showed high vascularity, suggesting possibility of a malignant tumour. Therefore, histology examination is important. Unfortunately, histological misdiagnosis can also occur and has been reported as high as 37%.<sup>6</sup> Adequate sampling is essential and in our case, the diagnosis was inconclusive probably related to inadequate tissue sampling of fine needle aspiration.

Histologically, primary angiosarcoma of the breast can be divided into three grades.<sup>7</sup> The tumour may exhibit features of more than one histological grade. The tumour spread occurs predominately through the blood stream and involvement of the lymphatics is unusual. A study by Chen *et al.* showed that the lung, skin and subcutaneous tissue, bone, liver, brain and ovary were the

most common sites of involvement in order of frequency.<sup>6</sup> The role of hormone in angiosarcoma of the breast is still poorly understood.<sup>8</sup> In our case, hormonal assay was not done.

Prognosis is variable and it depends upon tumour size and histological grade. The ten year overall survival rate is 80% for low grade tumours and only 20% for high grade tumours.<sup>2</sup> Patient with tumour size less than 4 cm has better survival rate.<sup>6</sup> Primary angiosarcoma of the breast has high mortality rate with only ten to 21% of patient disease free after five years.<sup>7,8</sup> Early diagnosis is important and our patient was fortunate that the tumour was detected at the early stage. Our patient has remained well and disease free after more than four years of follow-up.

In conclusion, primary angiosarcoma of the breast is a rare, but highly aggressive tumour. A careful workup for angiosarcoma should be considered in any vascular breast lesions. Early lesions can be detected through self breast examination and tumours diagnosed at early stages are always associated with a better outcome.

## REFERENCES

- 1:** Ohta M, Tokuda Y, Kuge S, et al. A case of angiosarcoma of the breast. *Jpn J Clin Oncol.* 1997; 27:91-4.
- 2:** Yang WT, Hennessy BT, Dryden MJ, Valero V, Hunt KK, Krishnamurthy S. Mammary angiosarcomas: imaging findings in 24 patients. *Radiology* 2007;242 : 725-34
- 3:** Luini A, Gatti G, Diaz J, et al. Angiosarcoma of the breast: the experience of the European Institute of Oncology and a review of the literature. *Breast Cancer Res Treat.* 2007; 105:81-5.
- 4:** Kinderyte R, Alisauskaite L, Juodzbaliene EB, Juozaityte E. Angiosarcoma of the breast: a case report and literature review. *Medicina (Kaunas).* 2006; 42:580-5.
- 5:** Glazebrook KN, Magut MJ, Reynolds C. Angiosarcoma of the breast. *AJR Am J Roentgenol.* 2008; 190:533-8.
- 6:** Chen KT. K, Kirkegaard DD, Bocian JJ. Angiosarcoma of the breast. *Cancer* 1980;46:268-71.
- 7:** Rosen PP, Kimmel M, Ernsberger D. Mammary angiosarcoma: The prognostic significance of tumor differentiation. *Cancer.* 1988; 62:2145-51.
- 8:** Antman KH, Corson J, Greenberger J, Wilson R. Multimodality therapy in the management of angiosarcoma of the breast. *Cancer* 1982;20:2000-3.