Brunei International Medical Journal

OFFICIAL PUBLICATION OF
THE MINISTRY OF HEALTH
AND
UNIVERSITI BRUNEI DARUSSALAM

Volume 16 13 December 2020 (27 Rabiulakhir 1442H)

IMAGING (CHEST RADIOGRAPHS) ABNORMALITIES IN PATIENTS WITH COVID-19 INFECTION IN BRUNEI DARUSSALAM.

Norhasyimah TAMIN[1], Nabilah AHMED[1], Islya Emma OTHMAN[1], Nur Adibah MD SALLEH[1], Tahir NADEEM[2], Babu Ivan MANI[3], Muhammad Syafiq ABDULLAH[1], Rosmonaliza ASLI[1], Raimiza Natalie MOMIN[1], Pui Ling CHONG[1], Vui Heng CHONG[1,3]

[1]Department of Medicine, RIPAS Hospital, Bandar Seri Begawan, Brunei Darussalam, [2]Department of Radiology, and [3]Department of Medicine, PMMPMHAMB Hospital, Tutong, Brunei Darussalam.

ABSTRACT

Introduction: The Corona Virus Infectious Disease (COVID-19) caused by Severe Acute Respiratory Syndrome Corona Virus 2 (SARS-COV-2) can affect any system but is primarily a respiratory disease. Manifestations can range from asymptomatic to severe, and chest radiological changes typically correlate with severity. Computed tomography scan is the best imaging, but is not widely available and plain chest radiography (CXR) remains the first line chest imaging. This study reports on CXR changes among patients with COVID-19 in Brunei Darussalam. **Materials and Methods:** All patient who had CXRs done were included in this study. Data were retrieved from a prospectively maintained database and anonymised for analyses. **Results**: Among 132 patients who had CXRs, 24 (18.2%) had radiological changes with mean age of 52.9 ± 11.3 years, which were significantly much older than those without CXR changes (35.9 ± 15.51 years). Of these 24 patients, 70.8% were men. Majority (70.8%) had symptoms on admission. Radiological changes occurred at a median of 3 days (range 0-8) of hospitalizations. Consolidation was the most common finding (62.5%), followed by ground glass opacities (37.5%). Twenty (87%) had resolution of radiological changes on CXRs at a median of 10 days (ranged from 9 to 16 days). Four patients developed progressive CXR changes consistent with acute respiratory distress syndrome requiring intubation with 3 going onto extracorporeal membrane oxygenation support (ECMO). The three patients on ECMO died with one successfully extubated and survive to discharge. Patients with radiological changes were significantly older (>40 years; OR 6.5) and have co-infections (OR 7.3) either at admission or during hospitalization on multivariate analysis. **Conclusions:** Common radiological manifestations include patchy consolidations and ground glass opacities. Changes were common at admission and can develop within 3 days of hospitalization. Older age groups (6.5 times) and those with co-infections (7.3 times) were more likely to develop chest xray abnormalities. Hence care monitoring and more aggressive management should be provided to these two groups.

Keywords: ARDS, Chest radiograph, Consolidation, COVID-19, Pneumonia, SARS-COV-2.

Brunei Int Med J. *2020;16:141-149*

ISSN 1560 5876 Print
ISSN 2079 3146 Online

Online version of the journal is available at www.bimjonline.com

Brunei International Medical Journal (BIMJ)
Official Publication of
The Ministry of Health
and
Universiti Brunei Darussalam

ISSN 1560-5876 Print
ISSN 2079-3146 Online

three relevant references should be included. Only images of high quality (at least 300dpi) will be acceptable.

Technical innovations
This section include papers looking at novel or new techniques that have been developed or introduced to the local setting. The text should not exceed 1000 words and should include not more than 10 figures illustration and references should not be more than 10.

Letters to the Editor
Letters discussing a recent article published in the BIMJ are welcome and should be sent to the Editorial Office by e-mail. The text should not exceed 250 words; have no more than one figure or table, and five references.

Criteria for manuscripts
Manuscripts submitted to the BIMJ should meet the following criteria: the content is original; the writing is clear; the study methods are appropriate; the data are valid; the conclusions are reasonable and supported by the data; the information is important; and the topic has general medical interest. Manuscripts will be accepted only if both their contents and style meet the standards required by the BIMJ.

Authorship information
Designate one corresponding author and provide a complete address, telephone and fax numbers, and e-mail address. The number of authors of each paper should not be more than twelve; a greater number requires justification. Authors may add a publishable footnote explaining order of authorship.

Group authorship
If authorship is attributed to a group (either solely or in addition to one or more individual authors), all members of the group must meet the full criteria and requirements for authorship described in the following paragraphs. One or more authors may take responsibility 'for' a group, in which case the other group members are not authors, but may be listed in an acknowledgement.

Authorship requirement
When the BIMJ accepts a paper for publication, authors will be asked to sign statements on (1) financial disclosure, (2) conflict of interest and (3) copyright transfer. The correspondence author may sign on behalf of co-authors.

Authorship criteria and responsibility
All authors must meet the following criteria: to have participated sufficiently in the work to take public responsibility for the content; to have made substantial contributions to the conception and design, and the analysis and interpretation of the data (where applicable); to have made substantial contributions to the writing or revision of the manuscript; and to have reviewed the final version of the submitted manuscript and approved it for publication. Authors will be asked to certify that their contribution represents valid work and that neither the manuscript nor one with substantially similar content under their authorship has been published or is being considered for publication elsewhere, except as described in an attachment. If requested, authors shall provide the data on which the manuscript is based for examination by the editors or their assignees.

Financial disclosure or conflict of interest
Any affiliation with or involvement in any organisation or entity with a direct financial interest in the subject matter or materials discussed in the manuscript should be disclosed in an attachment. Any financial or material support should be identified in the manuscript.

Copyright transfer
In consideration of the action of the BIMJ in reviewing and editing a submission, the author/s will transfer, assign, or otherwise convey all copyright ownership to the Clinical Research Unit, RIPAS Hospital, Ministry of Health in the event that such work is published by the BIMJ.

Acknowledgements
Only persons who have made substantial contributions but who do not fulfill the authorship criteria should be acknowledged.

Accepted manuscripts
Authors will be informed of acceptances and accepted manuscripts will be sent for copyediting. During copyediting, there may be some changes made to accommodate the style of journal format. Attempts will be made to ensure that the overall meaning of the texts are not altered. Authors will be informed by email of the estimated time of publication. Authors may be requested to provide raw data, especially those presented in graph such as bar charts or figures so that presentations can be constructed following the format and style of the journal. Proofs will be sent to authors to check for any mistakes made during copyediting. Authors are usually given 72 hours to return the proof. No response will be taken as no further corrections required. Corrections should be kept to a minimum. Otherwise, it may cause delay in publication.

Offprint
Contributors will not be given any offprint of their published articles. Contributors can obtain an electronic reprint from the journal website.

Aim and Scope of Brunei International Medical Journal

The Brunei International Medical Journal (BIMJ) is a six monthly peer reviewed official publication of the Ministry of Health under the auspices of the Clinical Research Unit, Ministry of Health, Brunei Darussalam.

The BIMJ publishes articles ranging from original research papers, review articles, medical practice papers, special reports, audits, case reports, images of interest, education and technical/innovation papers, editorials, commentaries and letters to the Editor. Topics of interest include all subjects that relate to clinical practice and research in all branches of medicine, basic and clinical including topics related to allied health care fields. The BIMJ welcomes manuscripts from contributors, but usually solicits reviews articles and special reports. Proposals for review papers can be sent to the Managing Editor directly. Please refer to the contact information of the Editorial Office.

Instruction to authors

Manuscript submissions

All manuscripts should be sent to the Managing Editor, BIMJ, Ministry of Health, Brunei Darussalam; e-mail: editor-in-chief@bimjonline.com. Subsequent correspondence between the BIMJ and authors will, as far as possible via should be conducted via email quoting the reference number.

Conditions

Submission of an article for consideration for publication implies the transfer of the copyright from the authors to the BIMJ upon acceptance. The final decision of acceptance rests with the Editor-in-Chief. All accepted papers become the permanent property of the BIMJ and may not be published elsewhere without written permission from the BIMJ.

Ethics

Ethical considerations will be taken into account in the assessment of papers that have experimental investigations of human or animal subjects. Authors should state clearly in the Materials and Methods section of the manuscript that institutional review board has approved the project. Those investigators without such review boards should ensure that the principles outlined in the Declaration of Helsinki have been followed.

Manuscript categories

Original articles

These include controlled trials, interventional studies, studies of screening and diagnostic tests, outcome studies, cost-effectiveness analyses, and large-scale epidemiological studies. Manuscript should include the following; introduction, materials and methods, results and conclusion. The objective should be stated clearly in the introduction. The text should not exceed 2500 words and references not more than 30.

Review articles

These are, in general, invited papers, but unsolicited reviews, if of good quality, may be considered. Reviews are systematic critical assessments of literature and data sources pertaining to clinical topics, emphasising factors such as cause, diagnosis, prognosis, therapy, or prevention. Reviews should be made relevant to our local setting and preferably supported by local data. The text should not exceed 3000 words and references not more than 40.

Special Reports

This section usually consist of invited reports that have significant impact on healthcare practice and usually cover disease outbreaks, management guidelines or policy statement paper.

Audits

Audits of relevant topics generally follow the same format as original article and the text should not exceed 1,500 words and references not more than 20.

Case reports

Case reports should highlight interesting rare cases or provide good learning points. The text should not exceed 1000 words; the number of tables, figures, or both should not be more than two, and references should not be more than 15.

Education section

This section includes papers (i.e. how to interpret ECG or chest radiography) with particular aim of broadening knowledge or serve as revision materials. Papers will usually be invited but well written paper on relevant topics may be accepted. The text should not exceed 1500 words and should include not more than 15 figures illustration and references should not be more than 15.

Images of interest

These are papers presenting unique clinical encounters that are illustrated by photographs, radiographs, or other figures. Image of interest should include a brief description of the case and discussion with educational aspects. Alternatively, a mini quiz can be presented and answers will be posted in a different section of the publication. A maximum of

IMAGING (CHEST RADIOGRAPHS) ABNORMALITIES IN PATIENTS WITH COVID-19 INFECTION IN BRUNEI DARUSSALAM.

Norhasyimah TAMIN[1], Nabilah AHMED[1], Islya Emma OTHMAN[1], Nur Adibah MD SALLEH[1], Tahir NADEEM[2], Babu Ivan MANI[3], Muhammad Syafiq ABDULLAH[1], Rosmonaliza ASLI[1], Raimiza Natalie MOMIN[1], Pui Ling CHONG[1], Vui Heng CHONG[1,3]

[1]Department of Medicine, RIPAS Hospital, Bandar Seri Begawan, Brunei Darussalam, [2]Department of Radiology, and [3]Department of Medicine, PMMPMHAMB Hospital, Tutong, Brunei Darussalam.

ABSTRACT

Introduction: The Corona Virus Infectious Disease (COVID-19) caused by Severe Acute Respiratory Syndrome Corona Virus 2 (SARS-COV-2) can affect any system but is primarily a respiratory disease. Manifestations can range from asymptomatic to severe, and chest radiological changes typically correlate with severity. Computed tomography scan is the best imaging, but is not widely available and plain chest radiography (CXR) remains the first line chest imaging. This study reports on CXR changes among patients with COVID-19 in Brunei Darussalam. **Materials and Methods:** All patient who had CXRs done were included in this study. Data were retrieved from a prospectively maintained database and anonymised for analyses. **Results**: Among 132 patients who had CXRs, 24 (18.2%) had radiological changes with mean age of 52.9 ± 11.3 years, which were significantly much older than those without CXR changes (35.9 ± 15.51 years). Of these 24 patients, 70.8% were men. Majority (70.8%) had symptoms on admission. Radiological changes occurred at a median of 3 days (range 0-8) of hospitalizations. Consolidation was the most common finding (62.5%), followed by ground glass opacities (37.5%). Twenty (87%) had resolution of radiological changes on CXRs at a median of 10 days (ranged from 9 to 16 days). Four patients developed progressive CXR changes consistent with acute respiratory distress syndrome requiring intubation with 3 going onto extracorporeal membrane oxygenation support (ECMO). The three patients on ECMO died with one successfully extubated and survive to discharge. Patients with radiological changes were significantly older (>40 years; OR 6.5) and have co-infections (OR 7.3) either at admission or during hospitalization on multivariate analysis. **Conclusions:** Common radiological manifestations include patchy consolidations and ground glass opacities. Changes were common at admission and can develop within 3 days of hospitalization. Older age groups (6.5 times) and those with co-infections (7.3 times) were more likely to develop chest xray abnormalities. Hence care monitoring and more aggressive management should be provided to these two groups.

Keywords: ARDS, Chest radiograph, Consolidation, COVID-19, Pneumonia, SARS-COV-2.

INTRODUCTION

A novel coronavirus, Severe Acute Respiratory Syndrome Corona Virus-2 (SARS-CoV-2) that causes Corona Virus Infectious Disease 2019 (COVID-19) was identified after a cluster of pneumonia of unknown cause was reported in Wuhan, China in December 2019.[1] Since, there has been rapid accumulation of data on this novel coronavirus which is rapidly evolving. The COVID-19 pandemic continues to rage on and as of 15th July 2020, there were 13,150,645 confirmed cases with 574,464

Corresponding author: Dr. Chong Vui Heng, Department of Medicine, PMMPMHAMB Hospital, Tutong, Brunei Darussalam.
E mail: chongvuih@yahoo.co.uk

death recorded worldwide.[2]

Early publications on COVID-19 radiological features have been largely focused on computed tomography (CT) scan findings due to its utilization as the first line imaging for screening of COVID-19 cases in China.[3-6] Patients with abnormal CT imaging typically showed ground glass opacities and consolidations. The reliance on CT as first line investigations for COVID-19 may place a significant burden for the radiology department especially in places with limited health resources. Furthermore, CT is not widely available and use of CT scan as a routine imaging for COVID-19 creates many barriers; infection control issues given that most centres have limited scanners and cannot dedicate a scanner solely for COVID-19 cases, chest radiograph (CXR) which can be portable remains the first line of radiological modality.[7] With this ongoing pandemic, it is crucial for clinicians to be familiar with COVID-19 features on CXRs.[8] Another modality that have been reported to be useful is ultrasound scan which is reported to show typical features but it's use is limited to assessment of pneumonia severity.[9] Furthermore, this modality is operator dependent.

Brunei Darussalam reported its first case of COVID-19 on 9th March 2020. In Brunei, all positive cases are admitted to the National Isolation Centre (NIC) for isolation and treatment. Contact tracing and testing were carried out for all contacts of confirmed cases and people with travel history. As of 27th July, Brunei Darussalam has remained free of new cases since 8th May 2020 and has recorded a total of 141 cases recorded, with 138 cases recovered and three deaths.[10] In our setting, CXRs is the imaging of choice as CT scan was not available in the designated hospital. This article reports on radiological abnormalities observed in patients with COVID-19 in Brunei Darussalam.

MATERIALS AND METHODS

Patients

All patients confirmed to have COVID-19 with positive reverse transcriptase polymerase chain reaction (RT-PCR) for SARS-CoV-2 were admitted to the NIC for isolation and treatment. Patients on admission had routine investigations that included complete blood count with differential counts, liver and renal profiles, inflammatory marker C-reactive protein (CRP), hepatitis B, C, HIV screening, and CXR. Cultures (sputum, blood, and urine) were done according to symptoms and suspicions. During hospitalization patients underwent repeated investigations as indicated. CXRs were repeated if there were new or persistent fever, respiratory symptoms, and elevated inflammatory markers. All CXRs were done using portable X-ray machines and reporting was done by a single radiologist stationed in the hospital. The COVID-19 management protocol for all patients has been previously reported.[11].

From 9 March to 6 June 2020, a total of 141 patients were admitted to NIC with confirmed diagnosis of COVID-19. All patients were specially coded and their demographics and clinical details were recorded into our Brunei Health Information Management System (Bru-HIMS) database and accessible only to clinicians and nurses directly managing the patients and also those with given access priviledges. Inclusion criteria for the study were all patients with confirmed COVID-19 infection and who had CXR performed. Of these, 132 patients were identified from Bru-HIMS to had CXRs performed during their isolation at NIC and form the study population. Nine patients who had did not have CXR performed during their isolation and management period either due to contraindications for CXR or categorized as mild disease based on admissions criteria and pediatric patients who did not have CXR done were excluded from the study.

Data collection

Patients demographic, clinical data and the reported findings of the CXRs were extracted for analyses without patients identifiers (BruHIMS number, names or national identity record number) but with their special COVID-19 coding for identification. Patients were divided into two groups; those with normal CXRs and those with abnormal CXRs reports for comparison.

Statistical analysis

Data analyses were performed using the SPSS IBM Version 23.0. Comparisons for continuous variables were carried out using Mann -Whitney test and for categorical variables, Fisher Exact test or Chi-Square test were used where appropriate. Level of significance was taken when p value was <0.05. Categorical variables significant on univariate analysis were entered into multivariate analysis and ORs were generated for significant results.

RESULTS

Patient characteristics

Of the 132 patients with CXR performed, there were only 24 (18.2%) patients who had abnormal CXR reports with radiological changes. These 24 patients with radiological changes were significantly older compared to those without radiological changes (Table I: 52.9 ± 11.3 years vs 35.93 ± 15.51 years respectively; *p<0.001*).

Majority of the 24 patients with radiological changes were men (n=17; 70.8%). The nationality breakdown was as follow: Bruneian (n=18, 75.0%), Bangladeshi (n=2, 8.3%), Filipino (n=1, 4.2%), Egyptian (n=1, 4.2%), Indian (n=1, 4.2%) and Nepalese (n=1, 4.2%). The most common comorbidities were hypertension (37.5%) and diabetes mellitus (16.7%). Eleven (45.8%) patients had travel history as the source of infections (Table I). Majority (n=17; 70.8%) had symptoms on admission. The most common presentations among patients with radiological changes was fever followed by coughing. During hospitalization, 37.5% (n=9) had documented desaturation (saturation <92% on room air) requiring oxygen supplementation. Twenty patients (83.3%) had up trending CRP with CXR changes. Eight patients had normal CRP on admissions.

Six patients were transferred to the ICU due to clinical deterioration and intubation and ventilatory supported were required in four patients (3 men; 1 woman). Of the four who were intubated and ventilated, three male patients died of severe septicemia. The remaining female patient who was intubated recovered and was successfully extubated from ventilator support. This patients and the other 20 patients with abnormal CXRs all recovered and were discharged alive. The 108 patients with normal CXRs and the 9 patients who did not have CXRs performed all recovered and got discharged home.

Radiological features

Eleven patients of the total 24 patients who had reported radiological abnormalities during hospitalisation, originally had normal CXRs on admission but developed radiological changes at a median of 3 days (range 0-8 days) of hospitalizations. Details of the CXRs changes/ abnormalities are shown in Table II. Consolidation, consisting mainly of bronchial pattern were the most common finding (62.5%), followed by ground glass opacities (37.5%). Excluding the three patients who had died, 52.4% had complete resolution of CXRs abnormalities at a median of 10 days (ranged from 9 to 16 days) at discharge. Of those who had residue abnormalities on CXR at discharge, all had complete resolution at follow up CXRs. Patients had a median of 4 CXRs (range 2 to 77). Figures 1 showed a patient with (a) normal admission CXR and (b&c) developed changes during hospitalization. Figures 2 show a patient who had (a) abnormal CXR of admission which (b) resolved during

Table I: COVID-19 patients' demographics, clinical symptoms, blood and radiological investigations with univariate comparisons between those with and those without CXR changes.

Variables		*With radiological changes (n=24)*	*With no radiological changes (n=108)*	*P values*
Age (mean ± SD in years)		52.9 ± 11.3	35.9 ± 15.51	***<0.001***
Age < 40 years		3	69 (63.9%)	***<0.001***
Age ≥ 40 years		21	39 (36.1%)	
Gender	Male	17 (70.8%)	65 (60.2%)	0.331
	Female	7 (29.2%)	43 (39.8%)	
Comorbid conditions	Overall (Yes)	14 (58.3)	32 (29.6)	***0.008***
	Diabetes (Yes)	3 (12.5)	6 (5.6)	0.222
	Hypertension (Yes)	8 (33.3)	13 (12.0)	***0.010***
	Dyslipidemia (Yes)	5 (20.8)	16 (14.8)	0.466
	Cardiac (Yes)	0 (0)	6 (5.6)	0.237
	Pulmonary (Yes)	2 (8.3)	4 (3.7)	0.325
Symptoms at admission (Yes)		18 (75.0)	71 (65.7)	0.381
Symptoms overall (Yes)		20 (83.3)	80 (74.1)	0.338
Symptoms (Yes)	Fever	8 (33.3)	30 (27.8)	0.587
	Cough	10 (41.7)	45 (41.7)	1.000
	Rhinorrhea	4 (16.7)	27 (25.0)	0.384
	Dyspnea	1 (4.2)	2 (1.9)	0.491
	Diarrhea	2 (8.3)	5 (4.6)	0.464
	Headache	1 (4.2)	10 (9.3)	0.414
	Myalgia	4 (16.7)	12 (11.1)	0.451
	Sore throat	3 (12.5)	8 (7.4)	0.414
Ct at diagnosis *	<26.0	11 (55.0)	59 (57.3)	0.850
	>26.0	9 (45.0)	44 (42.7)	
Serum albumin (gm/dL) **	<38.8	16 (76.2)	33 (32.7)	***<0.001***
	>38.8	5 (23.8)	68 (67.3)	
Lymphocytes ***	<1.82	16 (66.7)	53 (52.0)	0.193
	>1.82	8 (33.3)	49 (48.0)	
Neutrophils ***	<3.74	14 (58.3)	65 (63.7)	0.623
	>3.74	10 (41.7)	37 (36.3)	
Neutrophil/lymphocyte ratio ***	<2.55	15 (62.5)	72 (70.6)	0.441
	>2.55	9 (37.5)	30 (29.4)	
Overall coinfections	Yes	10 (41.7)	5 (4.6)	***<0.001***
	No	14 (58.3)	103 (95.4)	

Ct: Cycle threshold for RT-PCR analysis (surrogate marker for viral load, inverse correlation. Ct of 40.0 is negative).
*data available for 123 patients
**data available for 122 patients
*** data available for 126 patients

hospitalization. Figures 3a&b showed CXRs of a patient who had progressive changes without resolution.

Comparisons between COVID-19 patients with and without radiological changes

Based on univariate analysis, the 24 COVID-19 patients with radiological changes were older, more likely to have comorbidities especially hypertension, had lower serum albumin and with co-infections at admission (Table II). However, only age and presence of bacterial coinfections remained statistically significant for association with abnormal CXRs on multivariate analysis, with OR of 6.5 and 7.3 respectively (Table III).

DISCUSSION

Our study showed that CXRs were abnormal

Table II: Details of COVID-19 patients with radiological changes (N=24).

Characteristics		*n* (%)
CXR on admission	Normal	11 (45.8%)
	Abnormal	13 (54.2%)
Median duration to developing radiological changes if normal at admission (days)		3 (0-8)
Type of parenchymal abnormality	Consolidation	15 (62.5%)
	Ground glass opacities	9 (37.5%)
Laterality	Right lung	10 (41.7%)
	Left lung	5 (20.8%)
	Bilateral lung	9 (37.5%)
Complete resolution of CXR on discharge *	Yes	11 (52.4%)
	No	10 (47.6%)
Complete resolution at follow up*	Yes	21 (100%)

Note: * excluding patients who have died (n=3)

in almost one in five (18.2%) COVID-19 patients, and of these, almost half (8.3%) had abnormal CXR on admission with the remainders developing radiological abnormalities during hospitalization. The changes occurred at a median of 3 days (range 0-8 days) after admission. Radiological changes are more common in the first week of illness (median 4 -5 days of illness with most within two weeks) by which findings are less unless patients' conditions continue to deteriorate.[12] However, if we had included patients who did not have CXRs done, mostly those categorized as mild disease and unlikely to have radiological abnormalities, the incidence would be lower. One study from Italy on CXR changes (N=240) reported abnormal CXRs in 75% of patients, with changes seen within 2 days (63.3%), 3-5 days (72%), 6-9 days (81.2%) and beyond 9 days (83.9%).[13] To date, studies reporting on radiological changes including the Italian studies have mainly been on symptomatic to ill patients, in which large proportion are likely to have imaging abnormalities. Furthermore, many of the earlier reports especially from China had used CT scan as the imaging of choice contributed by delay in laboratory diagnosis. CT findings reported features that were characteristics to COVID-19.[3-7] CT is more sensitive than CXR and are reported to detect changes even before symptoms occur [12] and had resulted in higher rates of finding imaging abnormalities. Therefore, the incidence reported in the literature are much higher than what we have reported. Our study included all confirmed COVID-19 patients with majority having mild or no symptoms and we had only used CXRs.

The most common abnormalities reported in our study were consolidations (62.5%) as shown in Figure 1b and 3a, and ground glass opacities (37.5%) as shown in figure 2a, similar to what have been previously reported in the literature.[13,14] An Italian study on CXRs changes reported that ground glass opacities were the most common (68.8%), followed by reticular alteration (62.7%), and consolidation (39.4%). Alterations were bilateral in 73.3%. Upper, middle, and lower fields were involved in 36.7%, 79.4%, and 87.8%, respectively.[13] Lesions were peripheral in 49.4%, central in 11.1%, or both in 39.4%. Upper fields and central zones were significantly less involved (p <0.01).[13] Another study from Italy reported similar findings.[15] Most of the changes with exception of patients who had rapid progressions were mainly mild consolidations that were patchy in distributions. However, in CT imaging, these changes observed in CXRs will be more severe. CXR changes can be rapid as seen in patient in Figures 1, where the admission CXR was normal and within a few days had progressed to significant consolidations and ARDS, needing intubation and ventilatory

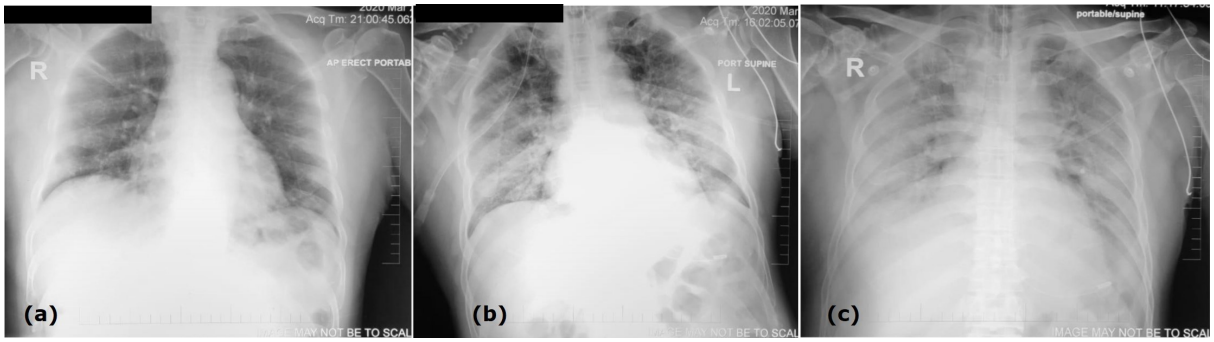

Figures 1: a) Normal admission CXR which rapidly progressed over the following three days (b and c) (patient died of ARDS, endocarditis and septicemia).

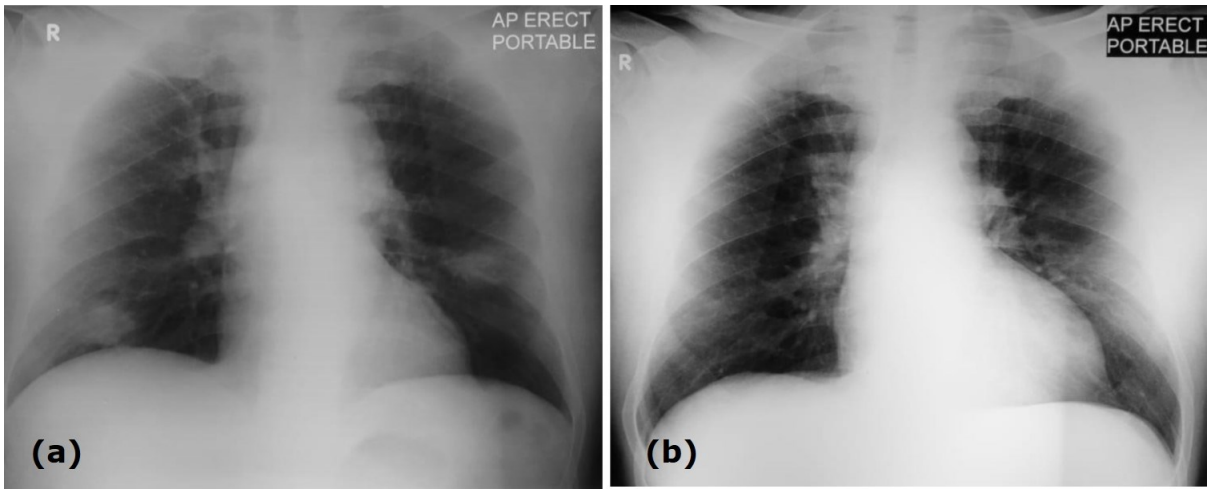

Figures 2: (a) Abnormal admission CXR, which (b) normalised before discharge.

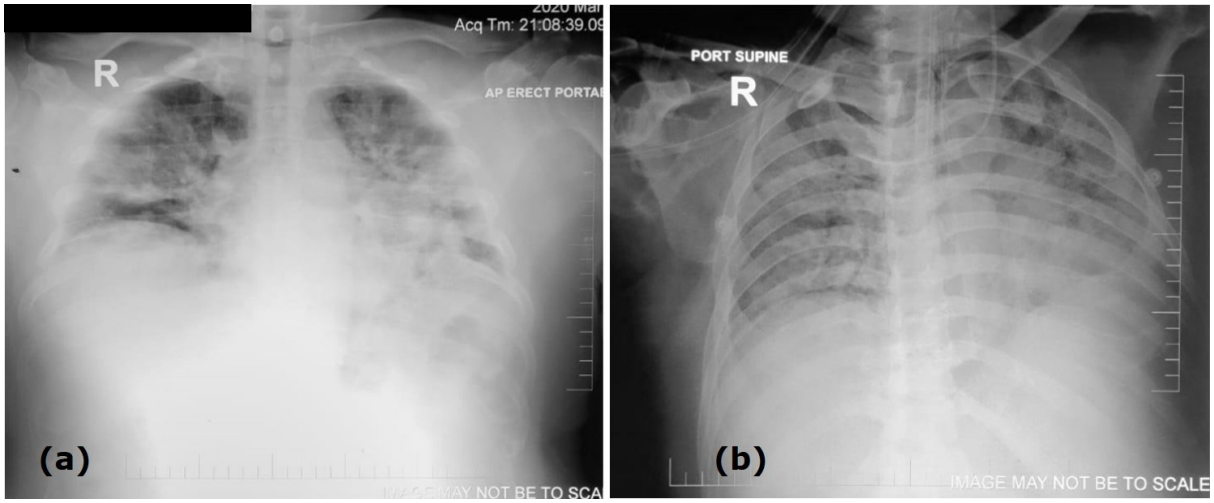

Figures 3: Patient with abnormal admission CXR (a) which progressed into acute respiratory distress syndrome with white out of both lungs (b) (patient died of ARDS).

Table III: Multivariate comparisons of COVID-19 patients with and those without CXR changes.

Variables	Odd ratio	P value	95% CI
Age (39 or less vs. ≥40)	**6.509**	***0.011***	**1.633 – 42.229**
Presence of overall bacterial co-infection	**7.293**	***0.007***	**1.800 – 40.451**
Absence of any comorbid condition	0.102	0.684	0.170 – 3.586
Absence of Hypertension	0.032	0.859	0.147 – 4.934
Serum albumin (gm/dL) (<38.8 vs. >38.8)	2.703	0.100	0.098 – 1.225

support. Development of lung bullae complicated by pneumothorax have also been reported and tended to occur in patient with severe disease as in one of our patients.[16] Among the sides of lungs affected, the right lung was more commonly affected with more than a third having bilateral involvements. Other studies have also reported bilateral involvement to be common, especially the lower lobes.[12,14] Peripheral involvements are more common than central involvement but generally, any part of the lungs can be affected. Radiological changes in COVID-19 patients based on CT scans have been categorised into five phases from pre-symptomatic to recovery (Table IV).[17]

Just over a third of patients had documented desaturation (<92%) associated with CXR changes. In contrast, increase in serum CRP level was noted in over 80% of patients who had CXR changes. CXR scores (changes) have been shown to correlate with several clinical and laboratory variables such as positive correlation with CRP, lactate dehydrogenase, and fever duration, and a negative correlation with oxygen saturation.[15] CXR findings are in line with those reported by CT scan studies.[15]

All our patients with CXR changes were categorized as moderate to severe and were treated with lopinavir/ritonanvir, some with hydroxychloroquine, which was later dropped from our treatment protocol due to cardiac side-effects.[11] Apart from the 3 patients who died, all radiological changes resolved at follow up. It is possible that some of the resolution might have occurred earlier and this was not captured as follow up CXRs after initial ones were done depending on condition of patients and not follow a set interval. In our case, once a patient improved clinically and biochemically, we did not necessarily proceed with a repeat CXR until closer to days of planned discharge. COVID-19 is reported to have long lasting consequences on the lung with chronic changes that include scarring and bronchiectasis, especially in patient with severe disease and pre-existing lung diseases such as chronic obstructive pulmonary airway disease.[18,19] To date, after more than 2 months since the last patient was discharged, all surviving patients have not presented to any government clinics or hospital for any respiratory problem. However, without doing CT scan imaging, mild residual lung damage that may not produce clinical symptoms can be missed.

Comparing patients with and without CXR changes, patients with changes were more likely to be older, have comorbid conditions in particular hypertension, lower serum albumin on admission, and develop overall bacterial co-infections. CXR changes correlat-

Table IV: Stages of radiological changes.

	Ultra-Early (1)	**Early (2)**	**Rapid progression (3)**	**Consolidation (4)**	**Dissipation (resolution) (5)**
Findings	-Prior to symptoms onset -Usually within 1-2 weeks of symptoms onset -Throat R-PCR +ve and IgM -ve	-Symptomatic (within 1-3 days) -Histology show congestion of alveolar capillaries resulting in alveolar and interlobular interstitial oedema	-Symptomatic (within 3-7 days) -Escalation in the hyperinflammatory response, Fibrous extensions that connect the alveoli begin to develop	-This phase coincides with the second week of clinical symptoms -The vascular congestion diminishes, and fibrosis predominate	-This phase occurs ~2-3 weeks after the initial symptomatic presentation -Healing and repair response within the lung
Radiological changes (Base on CT scan)	-Subpleural (typically scattered, multiple and bilateral ground glass opacities)	-progression of stage 1 changes with development of irregular interlobular septa	-progression with development of consolidations and air bronchogram may be visible	-improvement with decrease in size and densities of consolidation	-improvement with resolution, reduction in consolidation without or without reticular, bronchial or interlobular septae thickening

ed with severity of disease and some of the factors mentioned above have been associated with disease severity such as age[12], and comorbid conditions.[20] Being treated is just a consequence of disease severity, hence CXR changes.

There are several limitations with our study. First, our overall sample size and patients with radiological abnormalities were small and hence may affect our results. However, the sample size is the total number of patients and hence representative for the whole nation. Second, we only used CXRs and it is known that CT scan is more sensitive. Despite this, as discussed earlier on, it is impractical to consider CT scan as the modality of choice given that it may not be widely available and logistics issues such as arranging transport and porterage between isolation room/centre and radiological suite, which will create problems of infection control and safety, not to mention the disinfection of the CT suite and corridor post scanning. Furthermore CT scans may not available in the designated hospitals/Isolation centres for COVID-19. In addition, CT scan will pick radiological changes that may clinically be not relevant. Third, we did not do CXRs on a set regular interval which will mean that exact times of development and resolution of radiological abnormalities were estimates at best. However, despite this our findings are useful for daily practice in the management of COVID-19 patients during this pandemic especially in settings where the only imaging modality is CXRs.

CONCLUSION

In conclusion, CXRs abnormalities were seen in almost one in five patients with COVID-19, and of these, almost half had abnormalities at admissions and the remainder at a median of three days after admissions. Similar to what have been reported in the literature, common abnormalities were consolidations and ground glass opacities. Most of the changes were mild but can develop rapidly, and these patients typically require intensive care and ventilatory support. The longer the patients remain unwell and radiological changes progress, they tended not to do well often complicated by hospital acquired infections. It is important for clinicians to be familiar with common radiological changes on CXR so that patients can be managed appropriately.

DECLARATION

The authors declared that there is no conflict of interest and no financial conflict.

ACKNOWLEDGEMENT

We would like to acknowledge the tiredless effort of all the doctors, nurses, allied health professionals and support staff looking after COVID-19 patients at National Isolation Centre in Tutong during this pandemic.

REFERENCES

1: Huang C, Wang Y, Li X, et al. Clinical features of patients infected with 2019 novel coronavirus in Wuhan, China. Lancet. 2020; 395:497-506. [Accessed on 6th December 2020].

2: World Health Organisation. Coronavirus disease (COVID-19). Situation Report-177, 15 July 2020. [Accessed on 16th July 2020].

3: Lei J, Li J, Li X, Qi X. CT Imaging of the 2019 Novel Coronavirus (2019-nCoV) Pneumonia. Radiology. 2020; 295:18. doi: 10.1148/radiol.2020200236. [Accessed on 16th July 2020].

4: Chen N, Zhou M, Dong X, Qu J, Gong F, Han Y, et al. Epidemiological and clinical characteristics of 99 cases of 2019 novel coronavirus pneumonia in Wuhan, China: a descriptive study. Lancet. 2020; 395:507-13. doi: 10.1016/S0140-6736(20)30211-7. [Accessed on 16th July 2020].

5: Li M, Lei P, Zeng B, Li Z, Yu P, Fan B, et al. Coronavirus Disease (COVID-19): Spectrum of ct findings and temporal progression of the disease. Acad Radiol. 2020; 27:603-8. doi: 10.1016/j.acra.2020.03.003. [Accessed on 16th

July 2020].

6: Shi H, Han X, Zheng C. Evolution of CT Manifestations in a Patient Recovered from 2019 Novel Coronavirus (2019-nCoV) Pneumonia in Wuhan, China. Radiology. 2020; 295:20. doi: 10.1148/radiol.2020200269. [Accessed on 16th July 2020].

7: Shi H, Han X, Jiang N, Cao Y, Alwalid O, Gu J, et al. Radiological findings from 81 patients with COVID-19 pneumonia in Wuhan, China: a descriptive study. Lancet Infect Dis. 2020; 20:425-34. doi: 10.1016/S1473-3099(20) 30086-4. [Accessed on 6th December 2020].

8: Wong HYF, Lam HYS, Fong AH, Leung ST, Chin TW, Lo CSY, et al. Frequency and distribution of chest radiographic findings in covid-19 positive patients. Radiology. 2020; 296: E72-E78. doi: 10.1148/radiol.2020201160. [Accessed on 16th July 2020].

9: Zieleskiewicz L, Markarian T, Lopez A, Taguet C, Mohammedi N, Boucekine M, et al; AZUREA Network. Comparative study of lung ultrasound and chest computed tomography scan in the assessment of severity of confirmed COVID-19 pneumonia. Intensive Care Med. 2020 Jul 29:1 -7. doi: 10.1007/s00134-020-06186-0. [Accessed on 16th July 2020].

10: Ministry of Health, Brunei Darussalam. Media statement on the current COVID-19 infection in Brunei Darussalam. 07 May 2020. [Accessed on 16th July 2020].

11: Chong VH, Chong PL, Metussin D, Asli R, Momin RN, Mani BI, et al. Conduction abnormalities in hydroxychloroquine add on therapy to lopinavir/ritonavir in COVID-19. J Med Virol. 2020 May 13:10.1002/jmv.26004. doi: 10.1002/jmv.26004. [Accessed on 16th July 2020].

12: Liu Z, Ding L, Chen G, Zhao C, Luo X, Li X, et al. Clinical time features and chest imaging of 85 patients with COVID-19 in Zhuhai, China. Front Med (Lausanne). 2020; 7:209. doi: 10.3389/fmed.2020.00209. eCollection 2020. [Accessed on 16th July 2020].

13: Vancheri SG, Savietto G, Ballati F, Maggi A, Canino C, Bortolotto C, et al. Radiographic findings in 240 patients with COVID-19 pneumonia: time-dependence after the onset of symptoms. Eur Radiol. 2020 May 30:1-9. doi: 10.1007/s00330-020-06967-7. [Accessed on 16th July 2020].

14: Sun Z, Zhang N, Li Y, Xu X. A systematic review of chest imaging findings in COVID-19. Quant Imaging Med Surg. 2020; 10:1058-79. doi: 10.21037/qims-20-564. [Accessed on 16th July 2020].

15: Orsi MA, Oliva G, Toluian T, Valenti Pittino C, Panzeri M, Cellina M. Feasibility, reproducibility, and clinical validity of a quantitative chest X-Ray assessment for COVID-19. Am J Trop Med Hyg. 2020 Jul 2. doi: 10.4269/ajtmh.20-0535. [Accessed on 16th July 2020].

16: Yasukawa K, Vamadevan A, Rollins R. bulla formation and tension pneumothorax in a patient with COVID-19. Am J Trop Med Hyg. 2020 Jul 8. doi: 10.4269/ajtmh.20-0736. [Accessed on 16th July 2020].

17: Fatima S, Ratnani I, Husain M, et al. Radiological findings in patients with COVID-19. *Cureus.*2020 12(4): e7651. DOI 10.7759/ cureus.7651. [Accessed on 16th July 2020].

18: Lim ZY, Khoo HW, Hui TCH, Kok SSX, Kwan KEL, Young BE, et al. Variable computed tomography appearances of COVID-19. Singapore Med J. 2020 Apr 21. doi: 10.11622/ smedj.2020066. [Accessed on 16th July 2020].

19: Orsi MA, Oliva G, Cellina M. The lungs before and after COVID-19 pneumonia. Am J Trop Med Hyg. 2020; 103:6. doi: 10.4269/ajtmh.20-0357. [Accessed on 16th July 2020].

20: Li K, Wu J, Wu F, Guo D, Chen L, Fang Z, Li C. The clinical and chest CT features associated with severe and critical covid-19 pneumonia. Invest Radiol. 2020; 55:327-31. doi: 10.1097/ RLI.0000000000000672. [Accessed on 16th July 2020].