



OFFICIAL PUBLICATION OF
THE MINISTRY OF HEALTH,
BRUNEI DARUSSALAM

Brunei International Medical Journal

Volume 14

13 July 2018 (29 Syawal 1439H)

DENGUE RELATED OCULAR COMPLICATIONS: A CASE SERIES.

Nor Diyana ZAINAL NOOR, Aida Zairani MOHD ZAHIDIN, Wan Haslina WAN ABDUL HALIM.

Department of Ophthalmology, University Kebangsaan Malaysia Medical Centre (UKMMC), Jalan Yaacob Latif, 56 000 Cheras, Kuala Lumpur, Malaysia.

ABSTRACT

Dengue fever is a common mosquito-borne viral disease in the tropics with known multisystemic complications. Dengue related ocular manifestation is relatively unusual and may present with wide spectrum of ocular manifestations. We report three cases of uncommon dengue related ocular complications with different ocular manifestations, its management and sequelae. Early recognition and close monitoring of ocular sequelae from dengue infection is warranted to prevent irreversible visual damage

Keywords: Dengue fever, macular oedema, sixth nerve palsy, tonic pupil

Brunei Int Med J. 2018;14:84-87

Brunei International Medical Journal (BIMJ)

Official Publication of the Ministry of Health, Brunei Darussalam

EDITORIAL BOARD

Editor-in-Chief	William Chee Fui CHONG
Sub-Editors	Vui Heng CHONG Ketan PANDE
Editorial Board Members	Nazar LUQMAN Muhd Syafiq ABDULLAH Alice Moi Ling YONG Ahmad Yazid ABDUL WAHAB Jackson Chee Seng TAN Dipo OLABUMUYI Pemasiri Upali TELISINGHE Roselina YAAKUB Pengiran Khairol Asmee PENGIRAN SABTU Dayangku Siti Nur Ashikin PENGIRAN TENGAH

INTERNATIONAL EDITORIAL BOARD MEMBERS

Lawrence HO Khok Yu (Singapore)	Surinderpal S BIRRING (United Kingdom)
Emily Felicia Jan Ee SHEN (Singapore)	Leslie GOH (United Kingdom)
John YAP (United Kingdom)	Chuen Neng LEE (Singapore)
Christopher HAYWARD (Australia)	Jimmy SO (Singapore)
Jose F LAPENA (Philippines)	Simon Peter FROSTICK (United Kingdom)

Advisor

Wilfred PEH (Singapore)

Past Editors

Nagamuttu RAVINDRANATHAN
Kenneth Yuh Yen KOK

Proof reader

John WOLSTENHOLME (CfBT Brunei Darussalam)

Aim and Scope of Brunei International Medical Journal

The Brunei International Medical Journal (BIMJ) is a six monthly peer reviewed official publication of the Ministry of Health under the auspices of the Clinical Research Unit, Ministry of Health, Brunei Darussalam.

The BIMJ publishes articles ranging from original research papers, review articles, medical practice papers, special reports, audits, case reports, images of interest, education and technical/innovation papers, editorials, commentaries and letters to the Editor. Topics of interest include all subjects that relate to clinical practice and research in all branches of medicine, basic and clinical including topics related to allied health care fields. The BIMJ welcomes manuscripts from contributors, but usually solicits reviews articles and special reports. Proposals for review papers can be sent to the Managing Editor directly. Please refer to the contact information of the Editorial Office.

Instruction to authors

Manuscript submissions

All manuscripts should be sent to the Managing Editor, BIMJ, Ministry of Health, Brunei Darussalam; e-mail: editor-in-chief@bimjonline.com. Subsequent correspondence between the BIMJ and authors will, as far as possible via should be conducted via email quoting the reference number.

Conditions

Submission of an article for consideration for publication implies the transfer of the copyright from the authors to the BIMJ upon acceptance. The final decision of acceptance rests with the Editor-in-Chief. All accepted papers become the permanent property of the BIMJ and may not be published elsewhere without written permission from the BIMJ.

Ethics

Ethical considerations will be taken into account in the assessment of papers that have experimental investigations of human or animal subjects. Authors should state clearly in the Materials and Methods section of the manuscript that institutional review board has approved the project. Those investigators without such review boards should ensure that the principles outlined in the Declaration of Helsinki have been followed.

Manuscript categories

Original articles

These include controlled trials, interventional studies, studies of screening and diagnostic tests, outcome studies, cost-effectiveness analyses, and large-scale epidemiological studies. Manuscript should include the following; introduction, materials and methods, results and conclusion. The objective should be stated clearly in the introduction. The text should not exceed 2500 words and references not more than 30.

Review articles

These are, in general, invited papers, but unsolicited reviews, if of good quality, may be considered. Reviews are systematic critical assessments of

literature and data sources pertaining to clinical topics, emphasising factors such as cause, diagnosis, prognosis, therapy, or prevention. Reviews should be made relevant to our local setting and preferably supported by local data. The text should not exceed 3000 words and references not more than 40.

Special Reports

This section usually consist of invited reports that have significant impact on healthcare practice and usually cover disease outbreaks, management guidelines or policy statement paper.

Audits

Audits of relevant topics generally follow the same format as original article and the text should not exceed 1,500 words and references not more than 20.

Case reports

Case reports should highlight interesting rare cases or provide good learning points. The text should not exceed 1000 words; the number of tables, figures, or both should not be more than two, and references should not be more than 15.

Education section

This section includes papers (i.e. how to interpret ECG or chest radiography) with particular aim of broadening knowledge or serve as revision materials. Papers will usually be invited but well written paper on relevant topics may be accepted. The text should not exceed 1500 words and should include not more than 15 figures illustration and references should not be more than 15.

Images of interest

These are papers presenting unique clinical encounters that are illustrated by photographs, radiographs, or other figures. Image of interest should include a brief description of the case and discussion with educational aspects. Alternatively, a mini quiz can be presented and answers will be posted in a different section of the publication. A maximum of

three relevant references should be included. Only images of high quality (at least 300dpi) will be acceptable.

Technical innovations

This section include papers looking at novel or new techniques that have been developed or introduced to the local setting. The text should not exceed 1000 words and should include not more than 10 figures illustration and references should not be more than 10.

Letters to the Editor

Letters discussing a recent article published in the BIMJ are welcome and should be sent to the Editorial Office by e-mail. The text should not exceed 250 words; have no more than one figure or table, and five references.

Criteria for manuscripts

Manuscripts submitted to the BIMJ should meet the following criteria: the content is original; the writing is clear; the study methods are appropriate; the data are valid; the conclusions are reasonable and supported by the data; the information is important; and the topic has general medical interest. Manuscripts will be accepted only if both their contents and style meet the standards required by the BIMJ.

Authorship information

Designate one corresponding author and provide a complete address, telephone and fax numbers, and e-mail address. The number of authors of each paper should not be more than twelve; a greater number requires justification. Authors may add a publishable footnote explaining order of authorship.

Group authorship

If authorship is attributed to a group (either solely or in addition to one or more individual authors), all members of the group must meet the full criteria and requirements for authorship described in the following paragraphs. One or more authors may take responsibility 'for' a group, in which case the other group members are not authors, but may be listed in an acknowledgement.

Authorship requirement

When the BIMJ accepts a paper for publication, authors will be asked to sign statements on (1) financial disclosure, (2) conflict of interest and (3) copyright transfer. The correspondence author may sign on behalf of co-authors.

Authorship criteria and responsibility

All authors must meet the following criteria: to have participated sufficiently in the work to take public responsibility for the content; to have made substantial contributions to the conception and de-

sign, and the analysis and interpretation of the data (where applicable); to have made substantial contributions to the writing or revision of the manuscript; and to have reviewed the final version of the submitted manuscript and approved it for publication. Authors will be asked to certify that their contribution represents valid work and that neither the manuscript nor one with substantially similar content under their authorship has been published or is being considered for publication elsewhere, except as described in an attachment. If requested, authors shall provide the data on which the manuscript is based for examination by the editors or their assignees.

Financial disclosure or conflict of interest

Any affiliation with or involvement in any organisation or entity with a direct financial interest in the subject matter or materials discussed in the manuscript should be disclosed in an attachment. Any financial or material support should be identified in the manuscript.

Copyright transfer

In consideration of the action of the BIMJ in reviewing and editing a submission, the author/s will transfer, assign, or otherwise convey all copyright ownership to the Clinical Research Unit, RIPAS Hospital, Ministry of Health in the event that such work is published by the BIMJ.

Acknowledgements

Only persons who have made substantial contributions but who do not fulfill the authorship criteria should be acknowledged.

Accepted manuscripts

Authors will be informed of acceptances and accepted manuscripts will be sent for copyediting. During copyediting, there may be some changes made to accommodate the style of journal format. Attempts will be made to ensure that the overall meaning of the texts are not altered. Authors will be informed by email of the estimated time of publication. Authors may be requested to provide raw data, especially those presented in graph such as bar charts or figures so that presentations can be constructed following the format and style of the journal. Proofs will be sent to authors to check for any mistakes made during copyediting. Authors are usually given 72 hours to return the proof. No response will be taken as no further corrections required. Corrections should be kept to a minimum. Otherwise, it may cause delay in publication.

Offprint

Contributors will not be given any offprint of their published articles. Contributors can obtain an electronic reprint from the journal website.

DISCLAIMER

All articles published, including editorials and letters, represent the opinion of the contributors and do not reflect the official view or policy of the Clinical Research Unit, the Ministry of Health or the institutions with which the contributors are affiliated to unless this is clearly stated. The appearance of advertisement does not necessarily constitute endorsement by the Clinical Research Unit or Ministry of Health, Brunei Darussalam. Furthermore, the publisher cannot accept responsibility for the correctness or accuracy of the advertisers' text and/or claim or any opinion expressed.

DENGUE RELATED OCULAR COMPLICATIONS: A CASE SERIES.

Nor Diyana ZAINAL NOOR, Aida Zairani MOHD ZAHIDIN, Wan Haslina WAN ABDUL HALIM.

Department of Ophthalmology, University Kebangsaan Malaysia Medical Centre (UKMMC), Jalan Yaacob Latif, 56 000 Cheras, Kuala Lumpur, Malaysia.

ABSTRACT

Dengue fever is a common mosquito-borne viral disease in the tropics with known multisystemic complications. Dengue related ocular manifestation is relatively unusual and may present with wide spectrum of ocular manifestations. We report three cases of uncommon dengue related ocular complications with different ocular manifestations, its management and sequelae. Early recognition and close monitoring of ocular sequelae from dengue infection is warranted to prevent irreversible visual damage

Keywords: Dengue fever, macular oedema, sixth nerve palsy, tonic pupil

INTRODUCTION

Dengue fever (DF) is a mosquito-borne viral disease that is most commonly found in the tropics. It is caused by *Flaviviridae* virus and transmitted to humans by the bite of an infected female *Aedes Aegypti* mosquito. The incidence of dengue has grown dramatically around the world in recent decades with the highest incidence in Southeast Asia, India, and the American tropics. Worldwide cases of illness exceed 100 million per year.^{1,2}

Ocular complications related to DF have not been classically described. These ocular complications are not common and were previously considered rare. However, there have been several reports of wide spectrum of ocular complications ranging from mild to severe manifestations associated with DF in the last two decades.³⁻¹⁰

Corresponding author: Wan Haslina Wan Abdul Halim, Department of Ophthalmology, Universiti Kebangsaan Malaysia Medical Center (UKMMC), Jalan Yaacob Latif, Bandar Tun Razak, 56000 Kuala Lumpur, Malaysia.
Email: nordiyazanainal@gmail.com
Hp no: +60104045661/+60196679633

CASE REPORT

Case 1

A 34 years old Malay lady with no medical illness was diagnosed to have DF with transaminitis. She initially presented with fever for six days duration associated with warning sign of DF which was persistent vomiting. The diagnosis of DF was confirmed by positive dengue IgM antibodies. On the seventh day of illness, during the defervescence phase of DF, she noticed central blurring of vision in her left eye.

Ocular examination revealed visual acuity of 6/6 in the right eye (OD) and 6/36 in the left eye (OS). Bilateral anterior segment examination was unremarkable. Left fundus examination revealed macula oedema with retinal haemorrhages (Figure 1a). Right fundus examination revealed normal findings.

Laboratory investigations during the defervescence phase of DF showed low white cell counts of $2.80 \times 10^9/L$ and low platelet level of $102 \times 10^9/L$. Optical coherence tomography (OCT) of left macula showed presence of

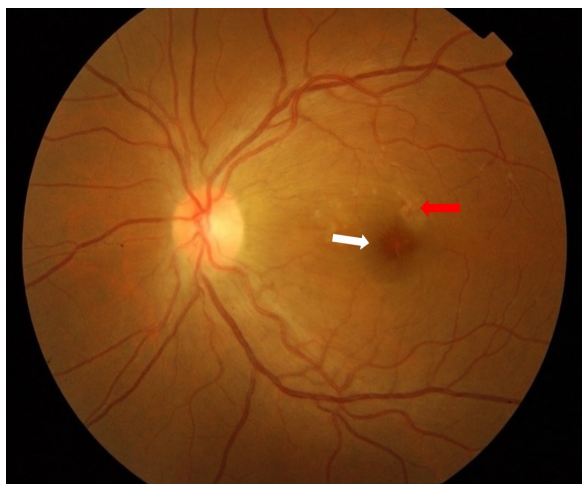


Figure 1a: Left fundus revealed macula oedema (white arrow) and retinal haemorrhages (red arrow).

intraretinal fluids (Figure 1b). Fundus fluorescein angiography (FFA) revealed evidence of leakage over the nasal region of the left fovea with no capillary fall out (Figure 1c).

She was treated with oral prednisolone 60mg daily with weekly 10mg tapering dose. Her right vision improved to 6/9 within one month with complete resolution of the macula oedema.

Case 2

A 25 years old healthy, Malay gentleman presented with symptomatic viral fever which was serologically confirmed as DF by detection of dengue specific IgM antibodies. He developed binocular diplopia during the reabsorption phase of DF in which blood investigations at that time revealed haematocrit level

of 46.4% with low white cell counts of $2.28 \times 10^9/L$ and normal platelet level of $219 \times 10^9/L$.

His visual acuity was 6/6 bilaterally (OU). Ocular examination revealed a right sided convergence squint and restriction of right lateral gaze consistent with right isolated sixth nerve palsy. His anterior segment, fundus and neurological examination were unremarkable. His Hess chart showed paralysis of the right lateral rectus muscle (Figure 2) and contrast-enhanced computed tomography (CECT) of the brain was normal.

He was started on intravenous methylprednisolone 500mg daily for 3 days followed by tapering dose of oral prednisolone. He regained full extra ocular muscle movement after 1 week post-completion of the course of intravenous steroid.

Case 3

A 38 years old, Malay lady with no medical illness, presented with sudden onset of painless blurred vision and glare in the right eye for three days duration. The ocular symptoms were preceded by two days history of fever, retro-orbital pain, headache with no warning signs of DF.

Her ocular examination revealed visual acuity of 6/6 OU with impaired accommodation in OD. There was presence of anisococ-

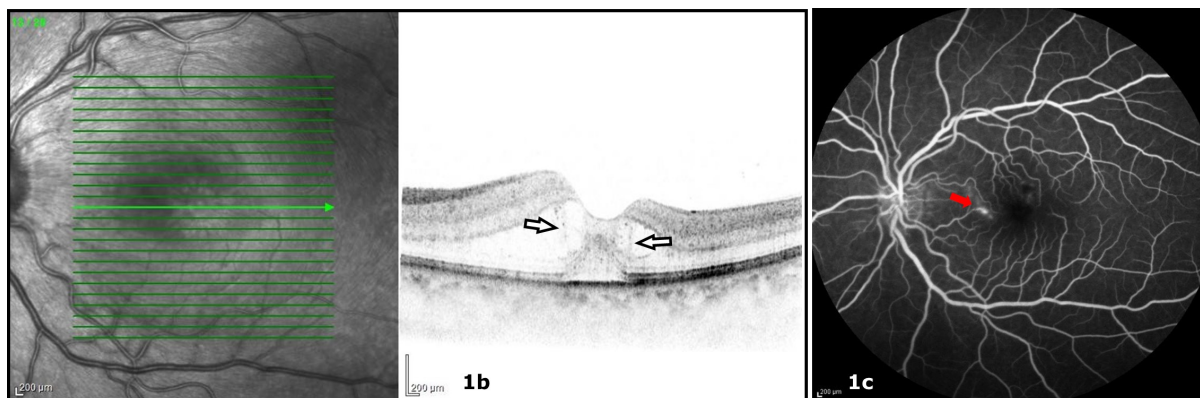


Figure 1b: OCT of left macula showed presence of intraretinal fluids (black-lined arrows) and Figure 1c: FFA of the left eye revealed evidence of leakage (red arrow) over the nasal region of the fovea.

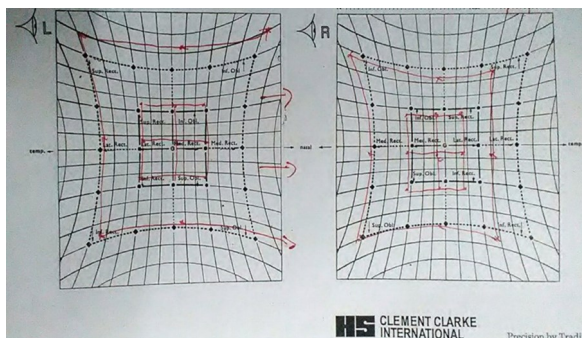


Figure 2: Hess chart showing right lateral rectus under action and left medial rectus over action suggestive for right lateral rectus palsy.

ria with right pupil of 6 mm and left pupil was 3 mm in the bright light (Figure 3a). The 0.125% pilocarpine test was positive with significant miosis in the right pupil while the left pupil showed no changes in the pupil size (Figure 3b). The intraocular, cranial nerve and other neurological examinations were unremarkable.

She was referred to neurology team for further evaluation and opinion regarding her clinical findings. Subsequent workups of syphilis serology, cerebrospinal fluid (CSF) analysis from lumbar puncture, CECT and magnetic resonance imaging (MRI) of the brain revealed normal results. Her blood investigations upon presentation revealed features of critical phase in DF with evidence of leucopenia $1.93 \times 10^9/L$, thrombocytopenia of $102 \times 10^9/L$ and haematocrit of 32.9%. The diagnosis of dengue fever was confirmed with positive dengue IgM and NS 1 antigen test.

She was treated symptomatically for DF and her right pupil mydriasis resolved after 3 months from the initial presentation.

DISCUSSION

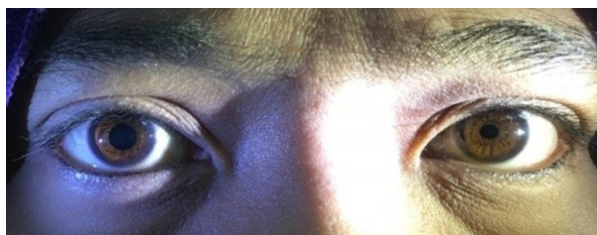


Figure 3a: Anisocoria (abnormal mydriasis in right pupil) was greater in bright light).

Dengue is the most common mosquito borne viral disease in human. It has become a major international public health concern with increasing prevalence.¹ Dengue related ophthalmic manifestation were once thought to be rare; however, a recent systematic review reported over 686 cases of DF related ocular complications.³ The precise pathophysiology of dengue ophthalmic complications is not well understood, but it was postulated to be due to thrombocytopenia and immune mediated reaction. The thrombocytopenic state of DF results in bleeding tendency which manifest as retinal haemorrhages. In addition, active immune mediated response may lead to plasma leakage leading to macular oedema and breakdown in the blood aqueous barrier resulting in uveitis and periphlebitis.⁴

The onset of ocular symptoms usually occurred within 1 week after the onset of fever.^{5,6} The delayed onset of ocular symptoms are most probably due to immune mediated mechanism rather than direct viral infection.⁴ The ocular symptoms also had been observed to correlate with the nadir of platelet level during the dengue infection.⁵ This correspond to our first and third cases, where the ocular symptoms were manifested during the thrombocytopenic state of DF with platelet count of $102 \times 10^9/L$ in both cases.

Dengue mostly affect the posterior segment of the eye with most common presenting complaint is blurring of vision and scotoma which may closely related to maculopathy.³ Dengue related maculopathy usually demonstrates features of vascular occlusion or vasculitis in FFA. A study by Bascal *et al.*, reported that FFA are able to pick up 25 % of eyes with vascular occlusion and 16% of eyes

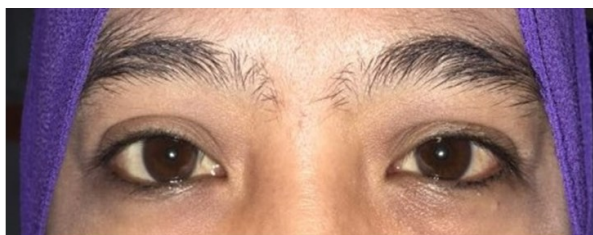

Figure 3b: Miosis in the right pupil and unchanged left pupil size, after application of 0.125% pilocarpine eyedrops.

with vascular leakage.⁷ As presented in our first case, the patient was diagnosed with dengue maculopathy with FFA result showing evidence of vascular leakage.

Dengue related neuro-ophthalmic complications are relatively uncommon. There are only few reported cases on dengue related neuro-ophthalmic complications especially abducens nerve palsy.^{9,10,11} The pathogenesis of neurological manifestations was believed to be immune-mediated and neurotrophic effects of dengue virus. In relation to our second case, the patient presented with delayed onset of right isolated abducens nerve palsy during the defervescence phase of dengue fever which suggest the immune mediated theory.

In addition to dengue related neuro-ophthalmic manifestations, this is the first reported case of DF presented with tonic pupil as presented in the third case. Tonic pupil is a rare condition that results from denervation of postganglionic parasympathetic fibres leading to a supersensitive response to weak cholinergic agonists (e.g. pilocarpine, 0.125%). The most common causes of tonic pupil are idiopathic. However, it may occur following infection, inflammation, trauma, tumour or ischemia.^{12,13} These possible causes were excluded in our third case. We postulate that the DF may have caused impairment of the ciliary ganglion parasympathetic function. This may also be an incidental finding.

CONCLUSION

Dengue is an endemic viral fever that may present with wide spectrum of ocular manifestations. The ocular related complications are becoming increasingly important as the dengue epidemic continues to rise in tropical countries. The overall prognosis is good with majority of cases being self-limiting. However, early diagnosis and prompt treatment hasten the recovery time and reduce ocular morbidity.

DISCLOSURES

The authors declared that they have no competing interests. Author acknowledged that consent has been obtained from patient to publish the images.

REFERENCES:

- 1: Ng AW, Teoh SC. Dengue eye disease. *Surv Ophthalmol.* 2015;60(2):106-14.
- 2: World Health Organization. Geneva: WHO; 2017. Dengue and severe dengue. [Assessed on 9 June 2018]. Available from: <http://www.who.int/mediacentre/factsheets/fs117/en/>
- 3: Yip VC, Sanjay S, Koh YT. Ophthalmic complications of dengue fever: a systematic review. *Ophthalmol Ther.* 2012;1(1):1-19. [Accessed date 9 June 2018]. Pdf available from: https://www.ncbi.nlm.nih.gov/pmc/articles/PMC4108139/pdf/40123_2012_Article_2.pdf
- 4: Lei HY, Yeh TM, Liu HS, et al. Immunopathogenesis of dengue virus infection. *J Biomed Sci.* 2001;8:377-88.
- 5: Lim WK, Mathur R, Koh A, et al. Ocular manifestations of dengue fever. *Ophthalmology.* 2004;111(11):2057-64.
- 6: Chan DP, Teoh SC, Tan CS, et al. Ophthalmic complications of dengue. *Emerg Infect Dis.* 2006;12(2):285-9. [Assessed on 9 June 2018]. <https://www.ncbi.nlm.nih.gov/pmc/articles/PMC3373088/pdf/05-0274.pdf>
- 7: Bacsal KE, Chee SP, Cheng CL, Flores JV. Dengue associated maculopathy. *Arch Ophthalmol.* 2007;125:501-10. [Assessed on 9 June 2018]. Full text available at <https://jamanetwork.com/journals/jamaophthalmology/fullarticle/419178>
- 8: Shivanthan MC, Ratnayake EC, Wijesiriwardena BC, et al. Paralytic squint due to abducens nerve palsy : A rare consequence of dengue fever. *BMC Infect Dis.* 2012;12(1):156. [Assessed on 9 June 2018]. Pdf available at <https://www.ncbi.nlm.nih.gov/pmc/articles/PMC3437196/pdf/1471-2334-12-156.pdf>
- 9: Mishra A, Shukla S, Aggarwal S, et al. Lateral rectus palsy in a case of dengue fever. *Med J Armed Forces India.* 2015;71(Suppl 1):S101-S103. [Assessed on 9 June 2018]. Pdf available at <https://www.ncbi.nlm.nih.gov/pmc/articles/PMC4529522/pdf/main.pdf>
- 10: Mazliha M, Boo YL, Chin PW. Isolated unilateral sixth cranial nerve palsy: A rare presentation of dengue fever. *Malays Fam Physician.* 2016;11(1):25-26. [Assessed on 9 June 2018]. Pdf available at <https://www.ncbi.nlm.nih.gov/pmc/articles/PMC5405330/pdf/MFP-11-25.pdf>
- 11: Tafakhori A, Aghamollaii V, Modabbernia A, et al. Adie's pupil during migraine attack: case report and review of literature. *Acta neurologica Belgica.* 2011;111:66-8. [Assessed on 9 June 2018]. Pdf available at https://pdfs.semanticscholar.org/b4ad/def40773dccaeb3cf666022e5b11619f958.pdf?_ga=2.60799085.1918659703.1530539120-1439514688.1530539120
- 12: Iannetti P, Spalice A, Iannetti L, et al. Residual and persistent Adie's pupil after pediatric ophthalmoplegic migraine. *Pediatric neurology.* 2009;41:204-6.