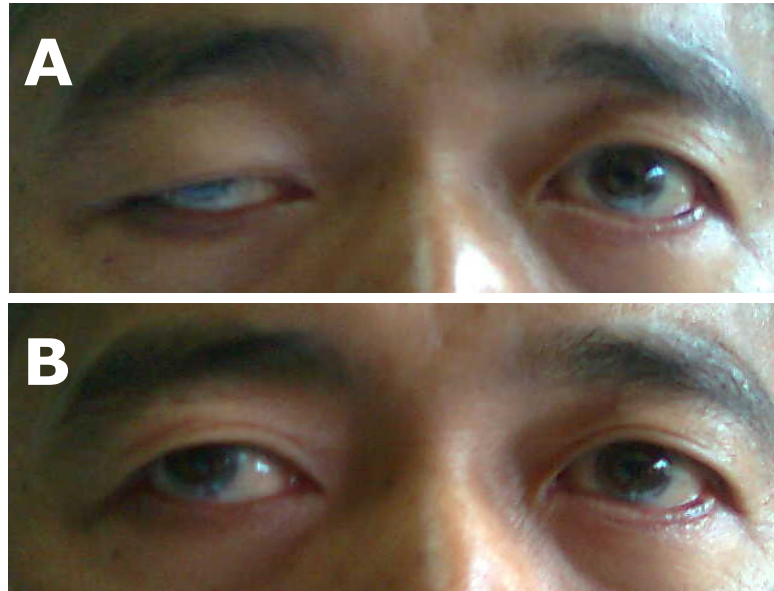


**Mohammad Athaillah ABDULLAH and Siti Nur Ashikin PENGIRAN TENGAH**



A gentleman in his forties presented with drooping of his right eye (**Panel A**). A test was done and there was improvement (**Panel B**).

**What is the diagnosis and what 'test' was done?**

**Answer:** refer to page 155

**Correspondence author:** SNA PENGIRAN TENGAH  
Rehabilitation Unit, Department of Medicine  
RIPAS Hospital, Brunei Darussalam  
Tel: +6732242424 Ext 7552  
E mail: ctengah@googlemail.com