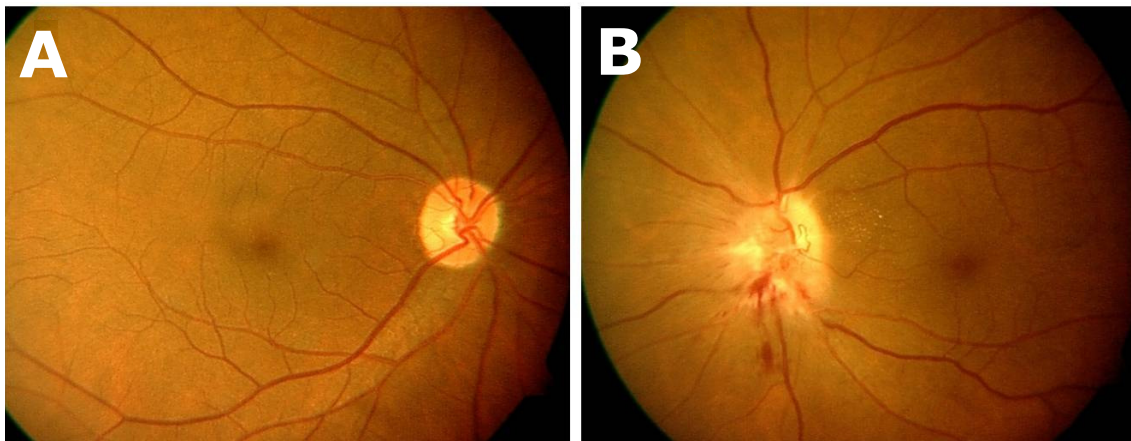


Nadir Ali MOHAMAD ALI

A 63-year-old gentleman presented with a two-day history of sudden, painless blurring of vision in the left eye, immediately after waking up in the morning. He is known to have had diabetes mellitus and hypertension for seven years, and a recent attack of angina pectoris. There was no history of trauma and no associated neurological abnormalities. Visual acuity was 6/6 in the right eye and 'Counting Fingers' in the left eye. Ocular examination was normal in the right eye (**Panel A**). Pupil examination of the left eye (**Panel B**) showed the presence of a relative afferent pupillary defect (RAPD), in addition to the above shown abnormality in the fundus.

What is the diagnosis?**Answer:** refer to page 153

Correspondence author: NA MOHAMAD ALI,
Department of Ophthalmology, RIPAS Hospital,
Bandar Seri Begawan BA 1710,
Brunei Darussalam.
Tel: +673 8223690
E mail: nadiramali@hotmail.com